

**HOT
NEWS**

IN HEMATOLOGY

Sindromi
linfoproliferative
ed oltre...

OTTIMIZZAZIONE DIAGNOSTICA

Stefano A. Pileri

BARI

7 luglio 2022

Villa Romanazzi Carducci

Disclosures of Stefano A. Pileri

Company name	Research support	Employee	Consultant	Stockholder	Speakers bureau	Advisory board	Other
BeiGene						X	
Takeda						X	
Roche					X		
Diatech						X	

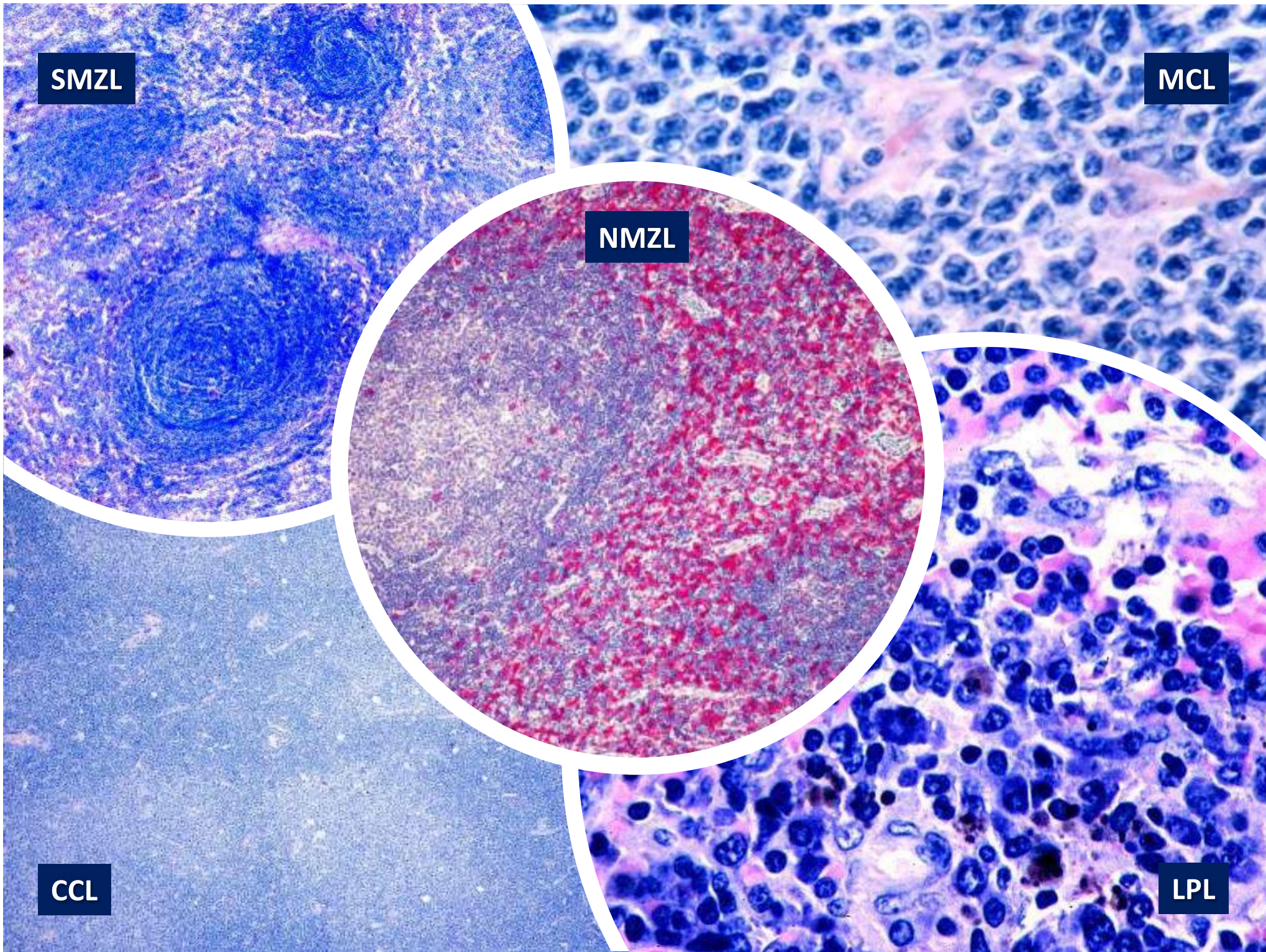
SMZL

MCL

NMZL

CCL

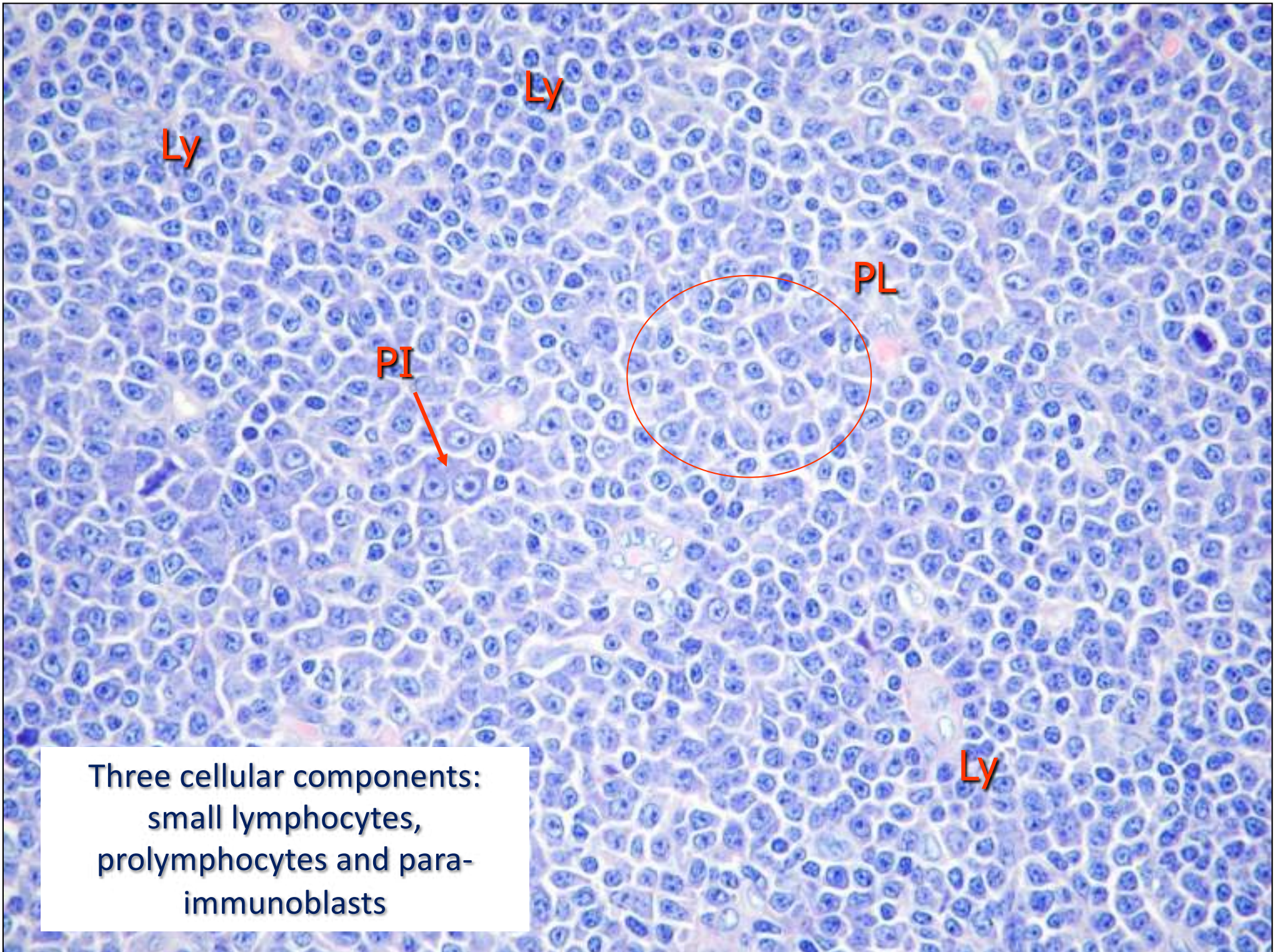
LPL



Chronic lymphocytic leukaemia/ small lymphocytic lymphoma

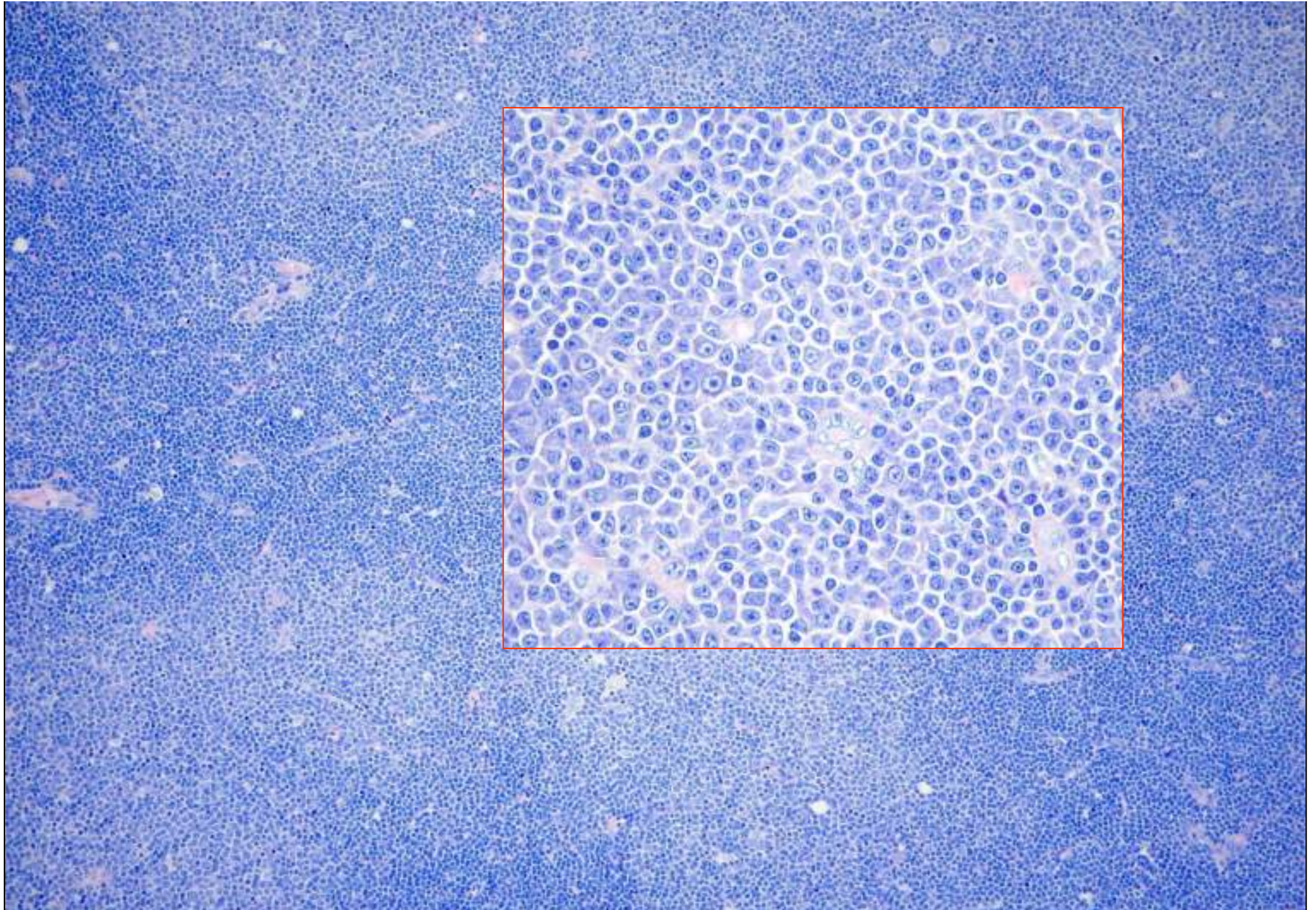
Definition

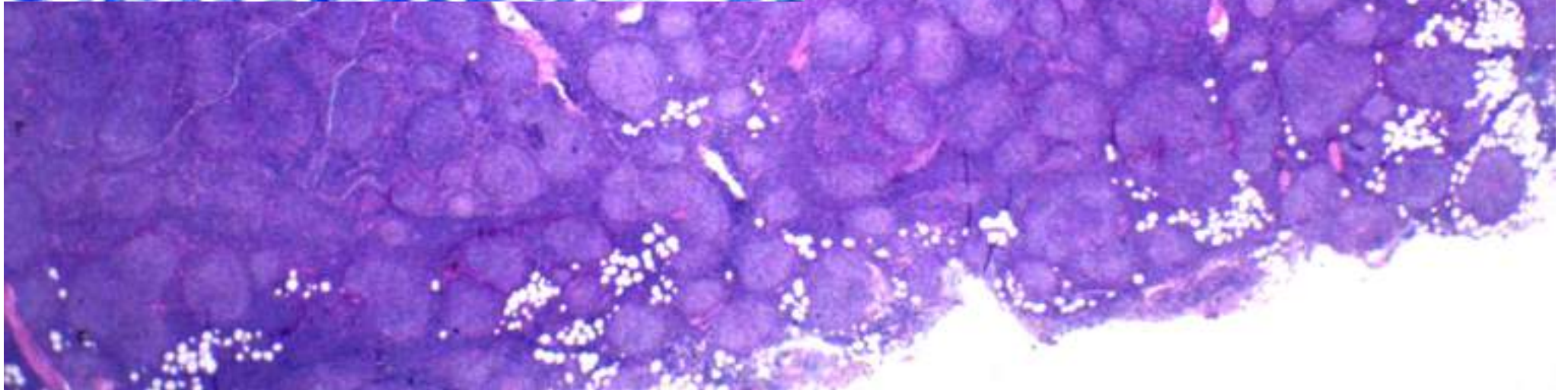
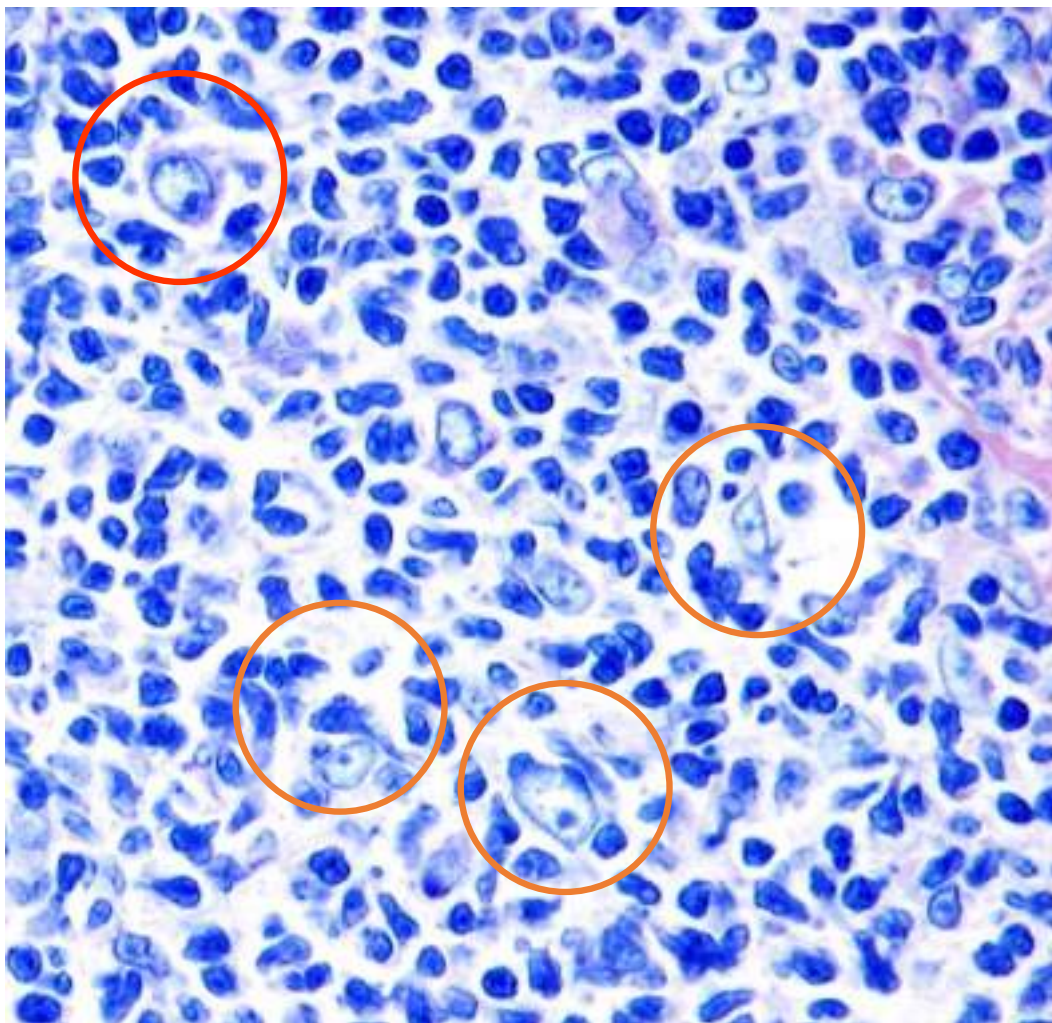
Chronic lymphocytic leukaemia/small lymphocytic lymphoma (CLL/SLL) is a neoplasm composed of monomorphic small mature B cells that coexpress CD5 and CD23. There must be a monoclonal B-cell count $\geq 5 \times 10^9/L$, with the characteristic morphology and phenotype of CLL in the peripheral blood. Individuals with a clonal CLL-like cell count $< 5 \times 10^9/L$ and without lymphadenopathy, organomegaly, or other extramedullary disease are considered to have monoclonal B-cell lymphocytosis. Although CLL and SLL are the same disease, the term SLL is used for cases with a circulating CLL cell count $< 5 \times 10^9/L$ and documented nodal, splenic, or other extramedullary involvement [1523].



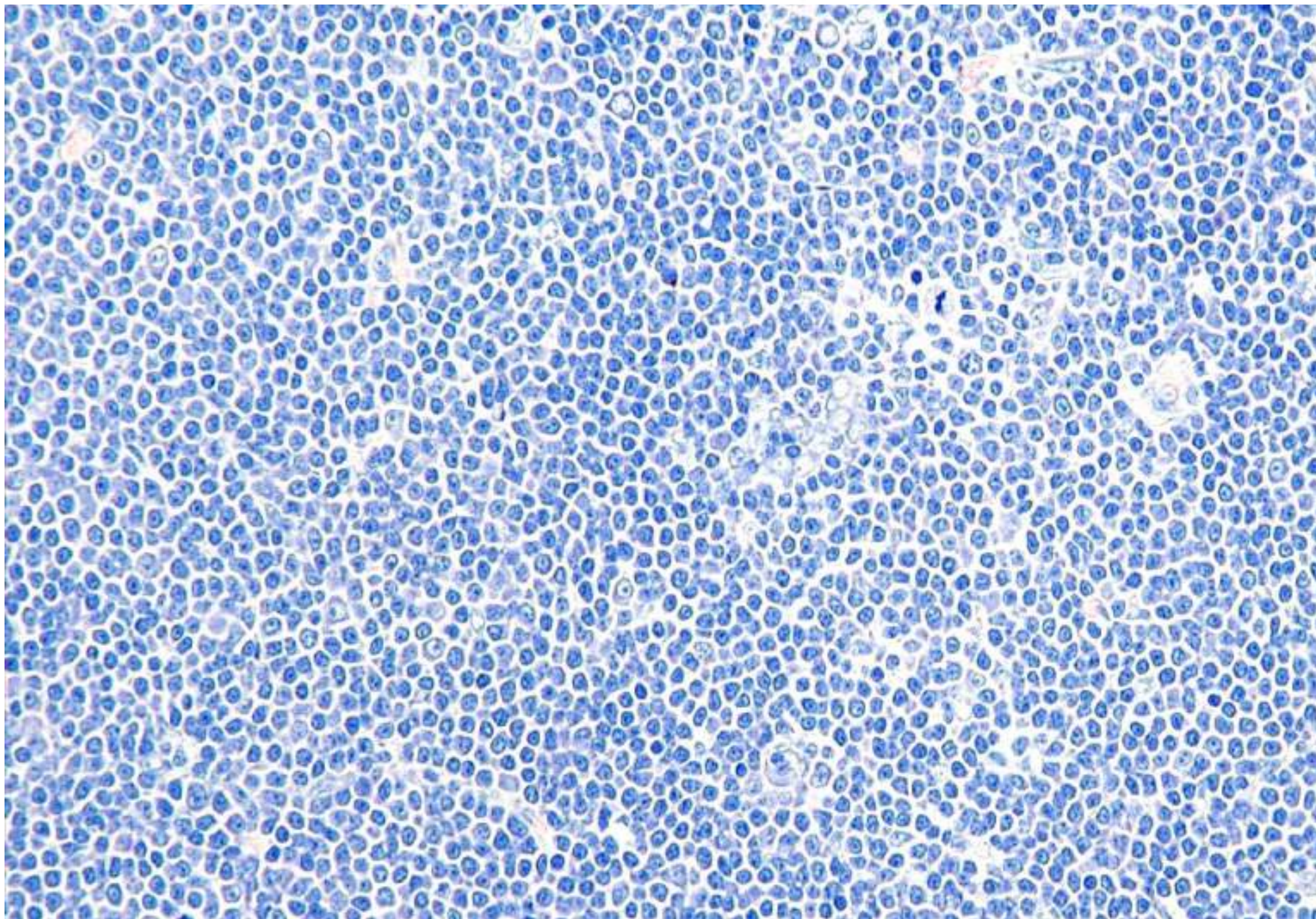
Three cellular components:
small lymphocytes,
prolymphocytes and para-
immunoblasts

Pseudo-follicular pattern: 85% of cases (lymph node, bone-marrow, extranodal sites)





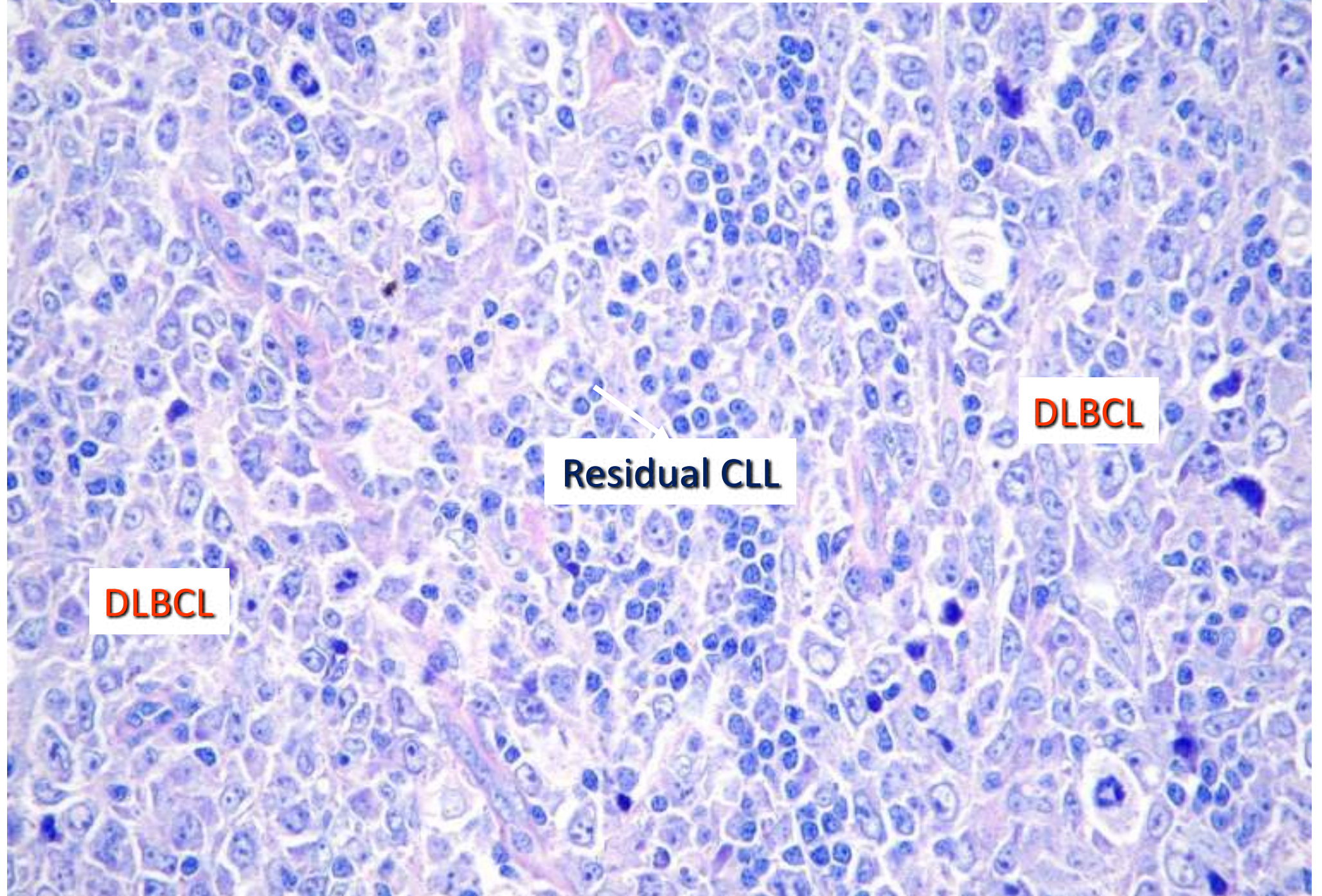
Diffuse growth pattern: 7% of cases; scanty prolymphocytes and paraimmunoblasts



The image is a composite of two histological micrographs. The left half shows a low-magnification view of a tissue section stained with hematoxylin and eosin (H&E), displaying a dense population of cells with pink cytoplasm and purple nuclei. The right half shows a high-magnification view of the same tissue, highlighting individual cells with large, round, blue-stained nuclei and scant cytoplasm, characteristic of a high-grade neoplasm. A white diamond-shaped graphic is superimposed over the center of the image, containing the text 'Tumor-forming'.

Tumor-forming

Richter Syndrome – DLBCL type: related or unrelated (EBV+)

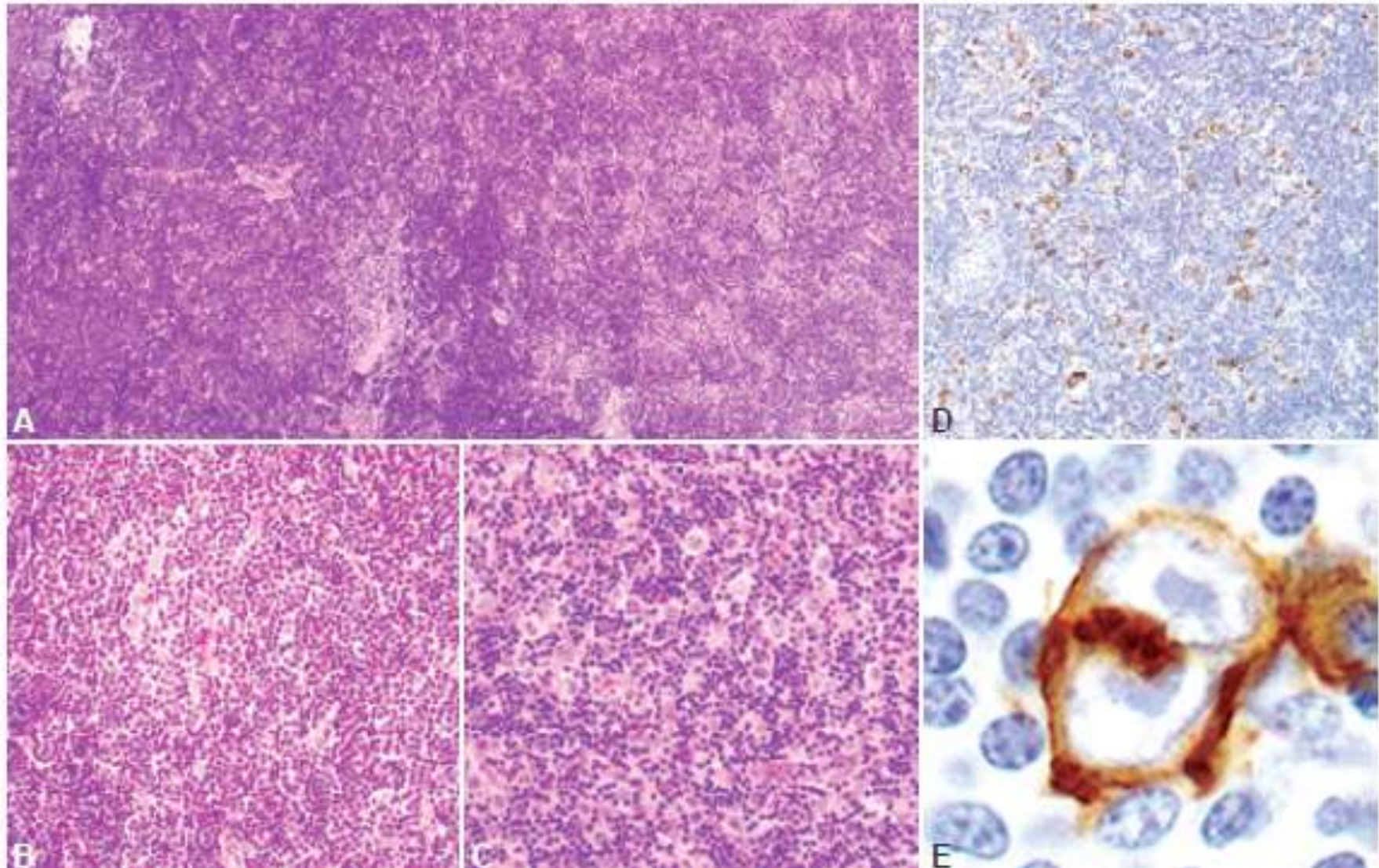


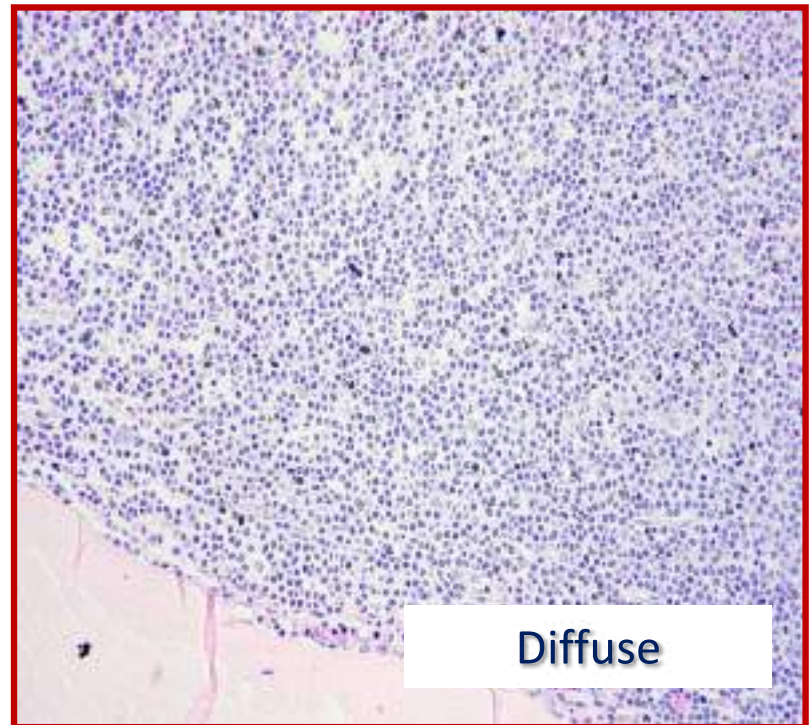
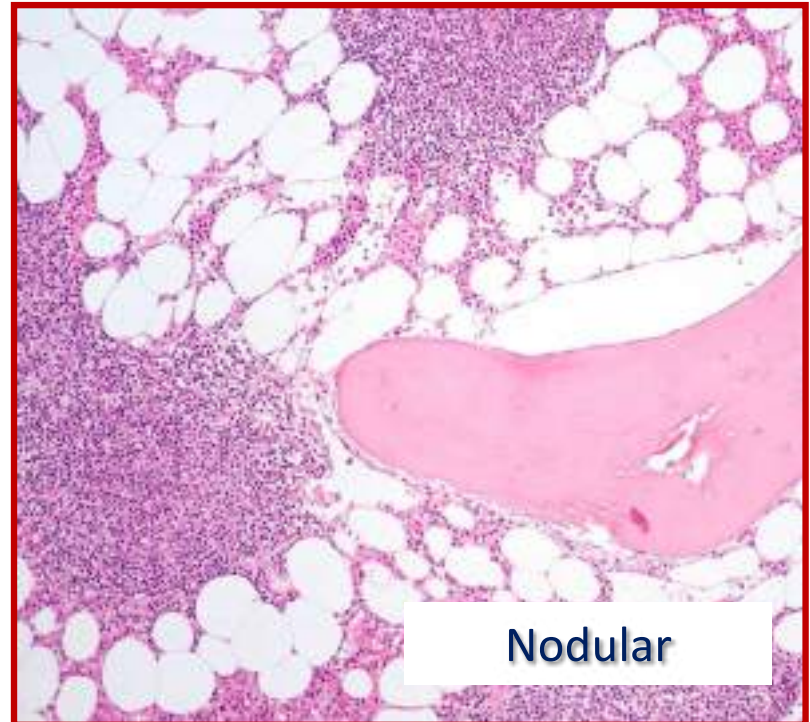
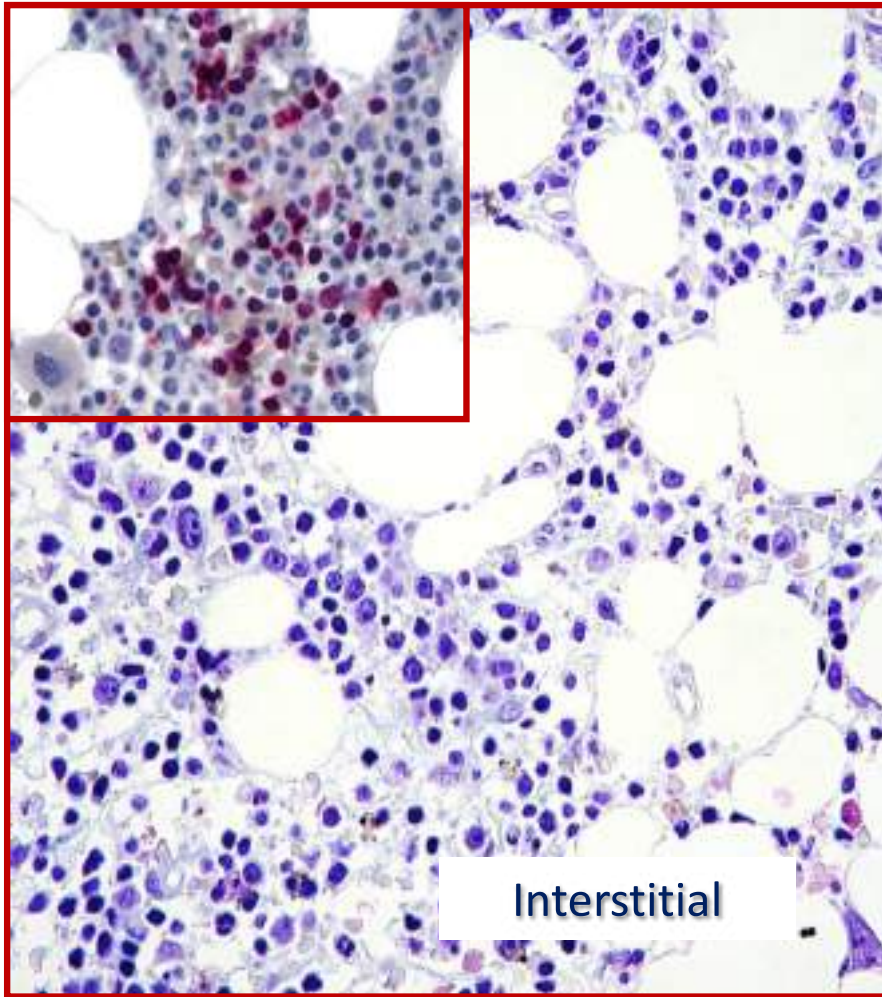
DLBCL

Residual CLL

DLBCL

Richter Syndrome – Hodgkin type





Bone-marrow involvement
Pseudo-follicles (clear centres)
Useful for the diagnosis

Phenotype

CD20 + (weak but stronger in pseudo-follicles)

CD19, CD22, CD79a (homogeneously strong)

CD5 + (variable but stronger in pseudo-follicles)

CD23 + (variable but stronger in pseudo-follicles)

IgM/IgD+ (weak)

CD200 +

LEF1 +

ZAP70 (related to the IGVH mutational status: 85% concordance)

IRF4 (+ in pseudo-follicles)

Cyclin D1 - (rare cases with weak, partial staining in the absence of t(11;14) and SOX11 positivity)

IRTA1, MNDA, T-bet -

CD10, BCL6, LMO2 -

Ki-67 + (higher in pseudo-follicles)

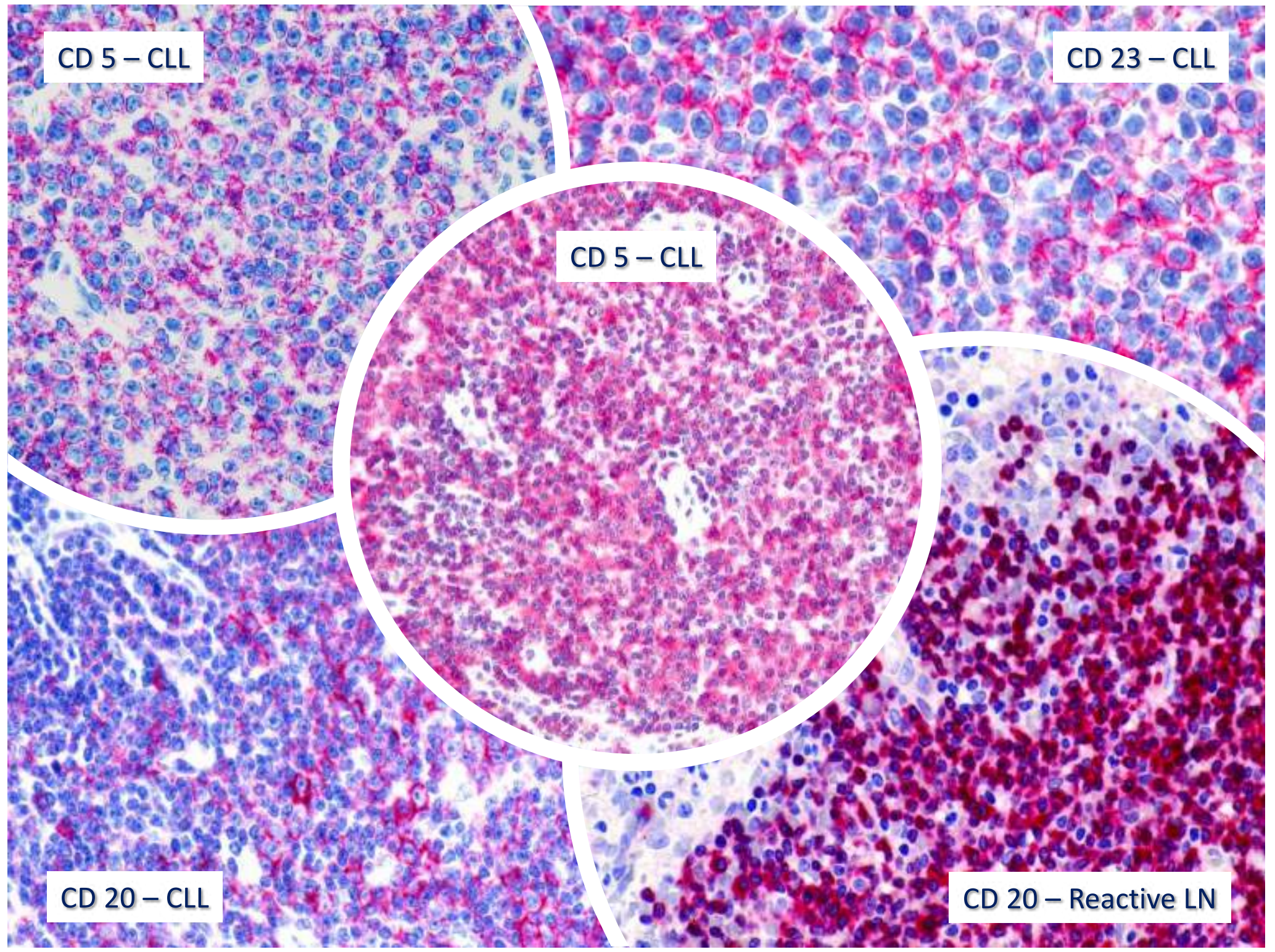
CD 5 – CLL

CD 23 – CLL

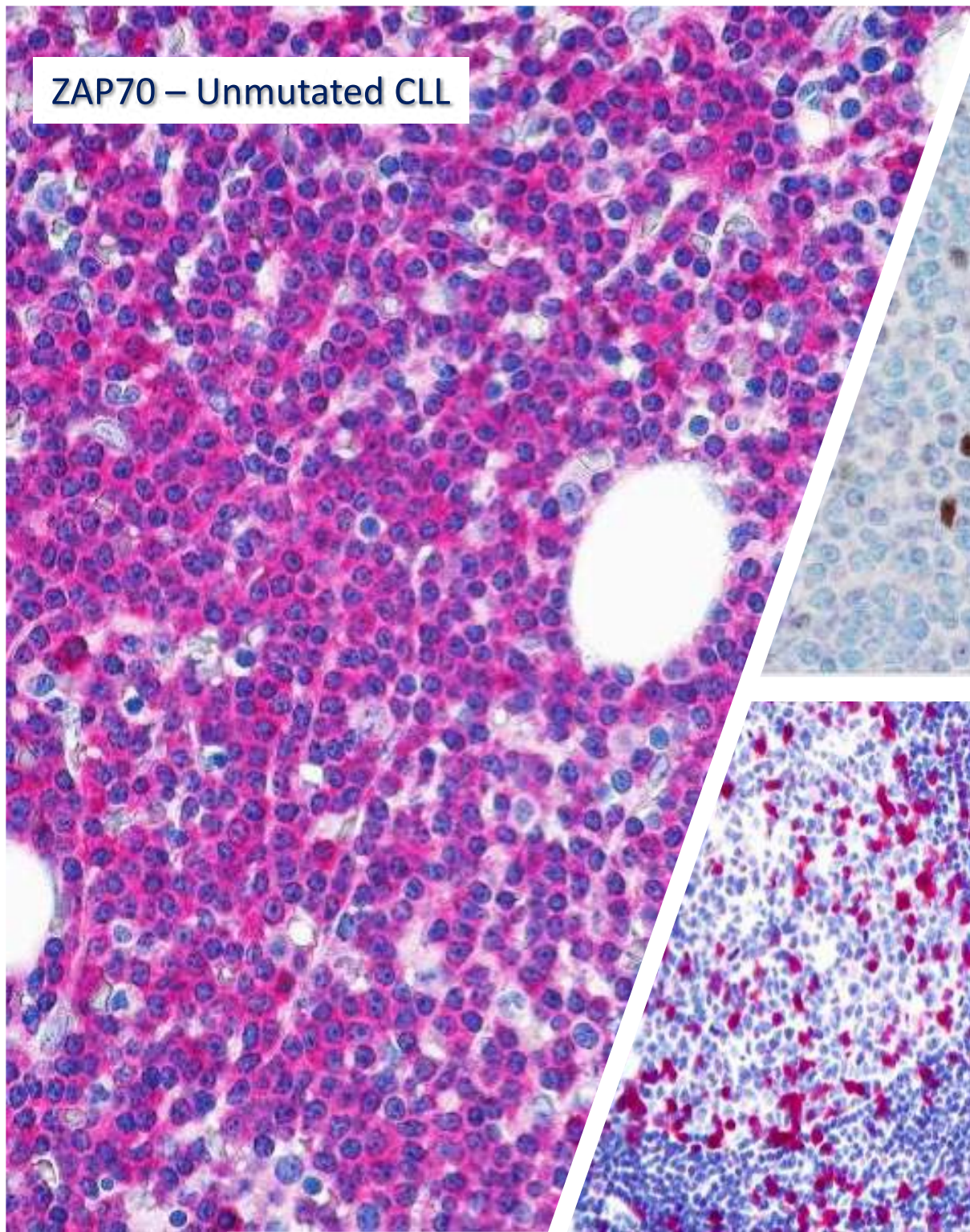
CD 5 – CLL

CD 20 – CLL

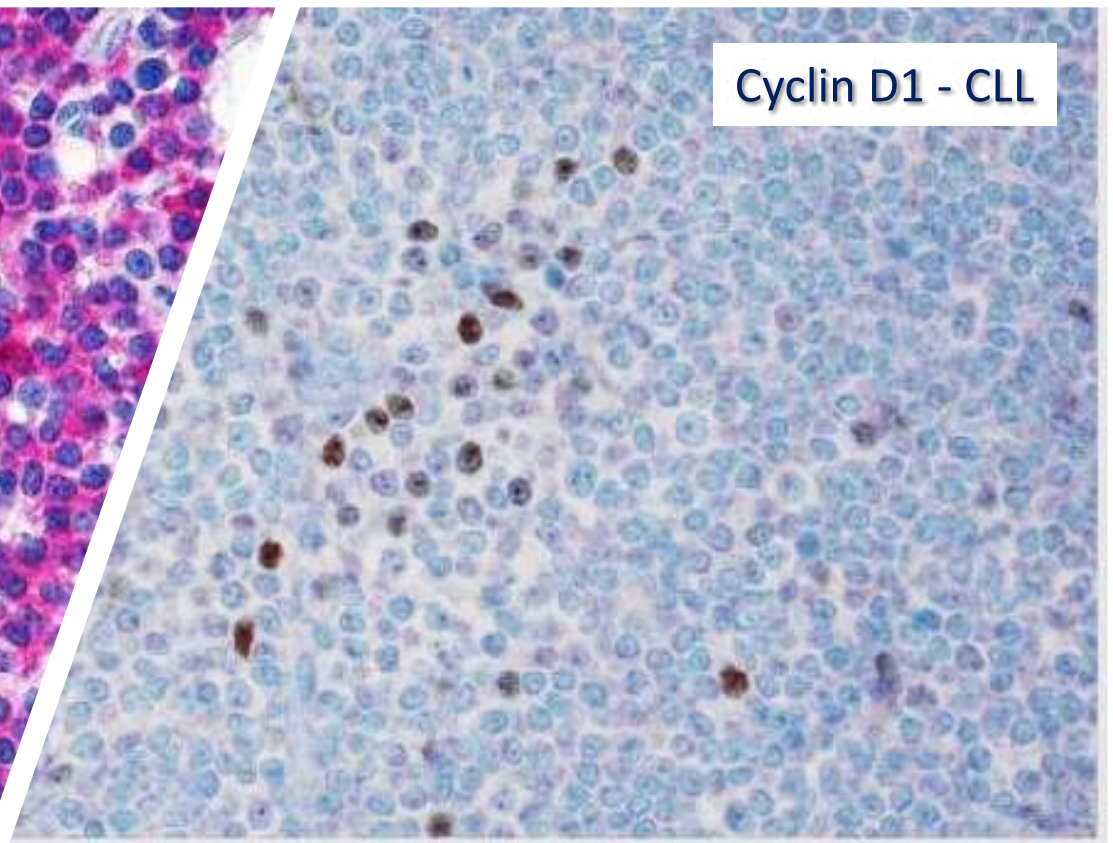
CD 20 – Reactive LN



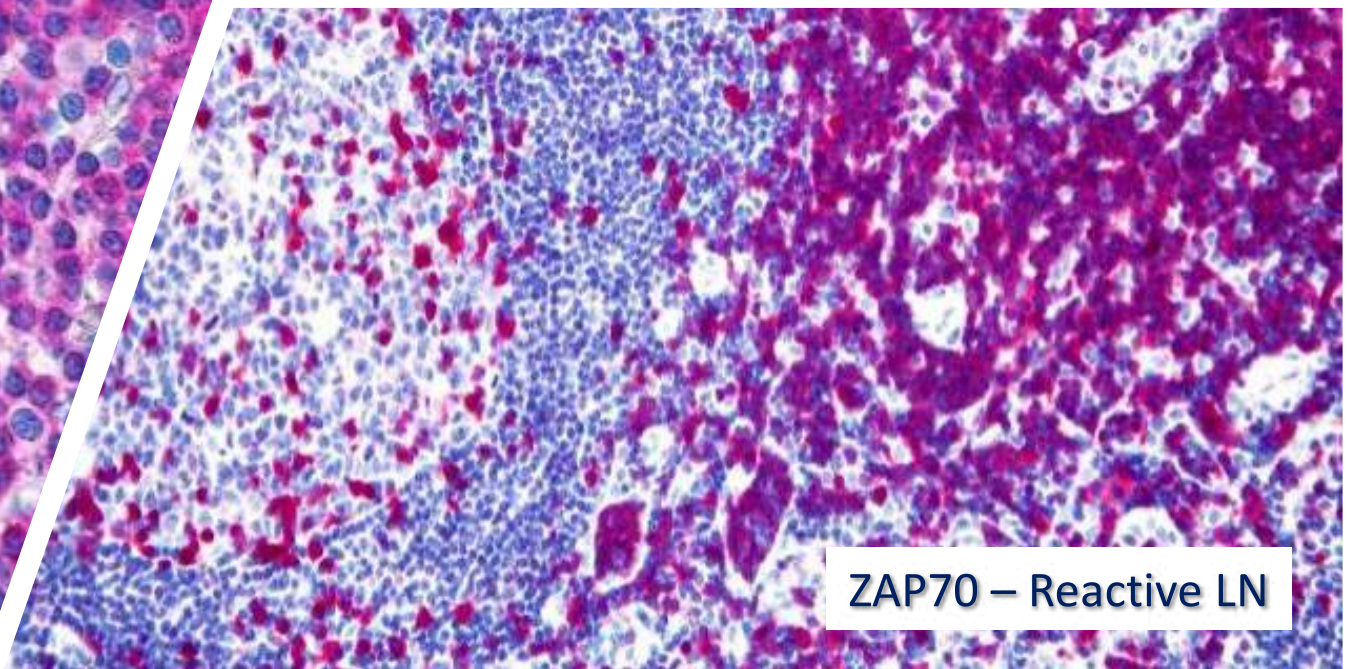
ZAP70 – Unmutated CLL



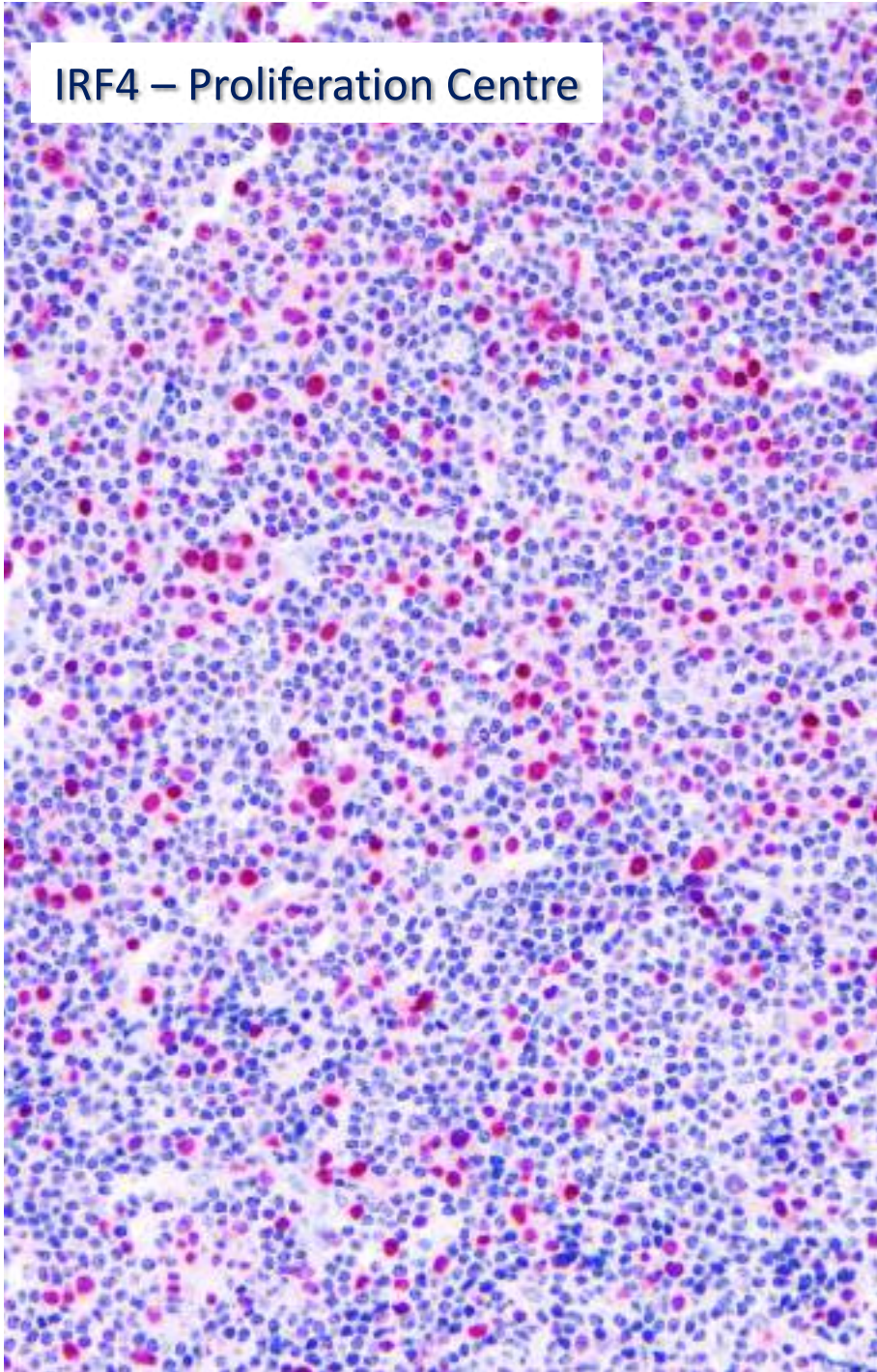
Cyclin D1 - CLL



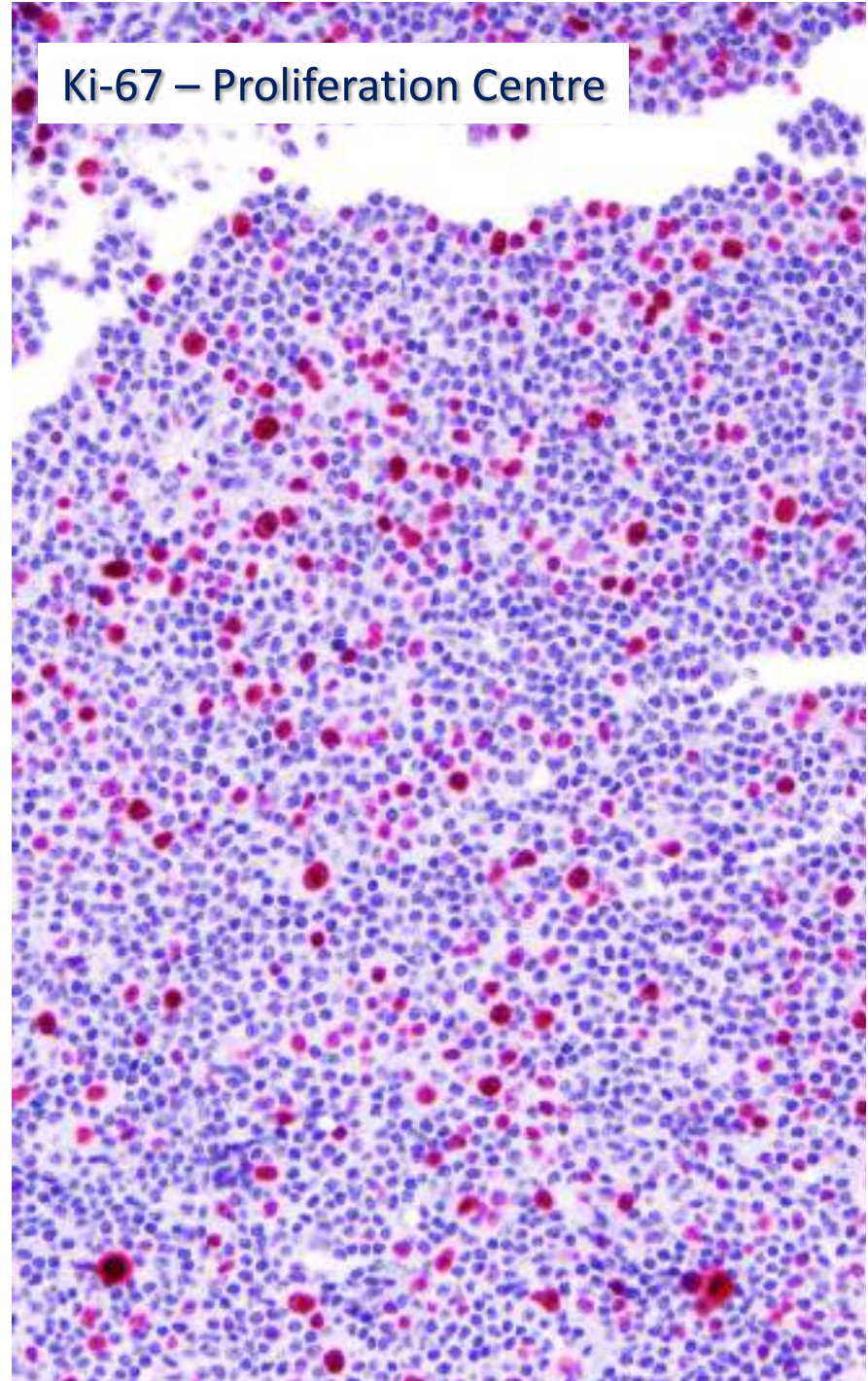
ZAP70 – Reactive LN



IRF4 – Proliferation Centre

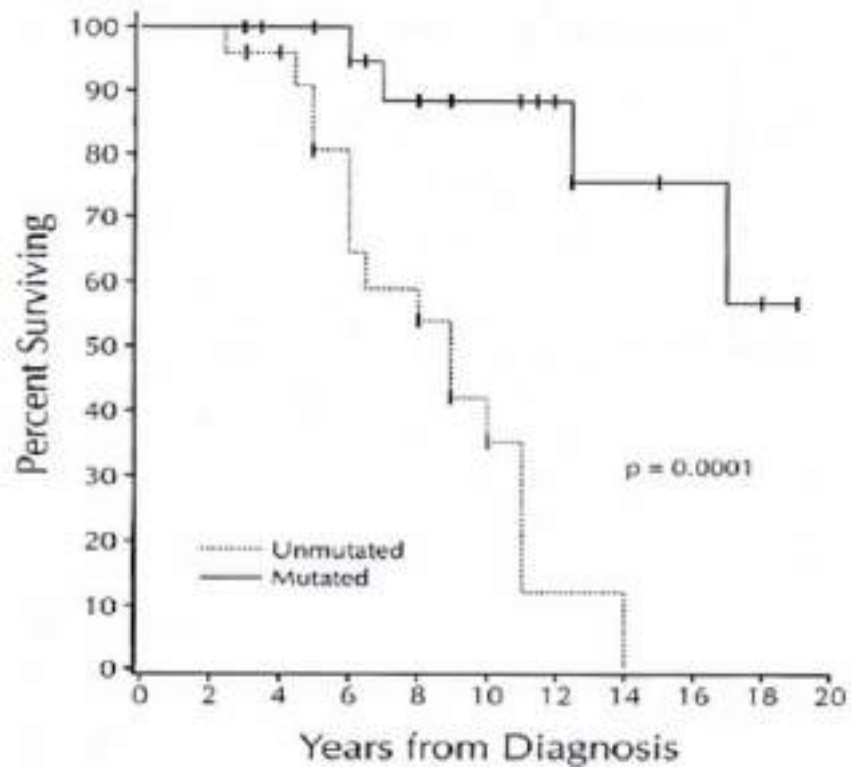


Ki-67 – Proliferation Centre

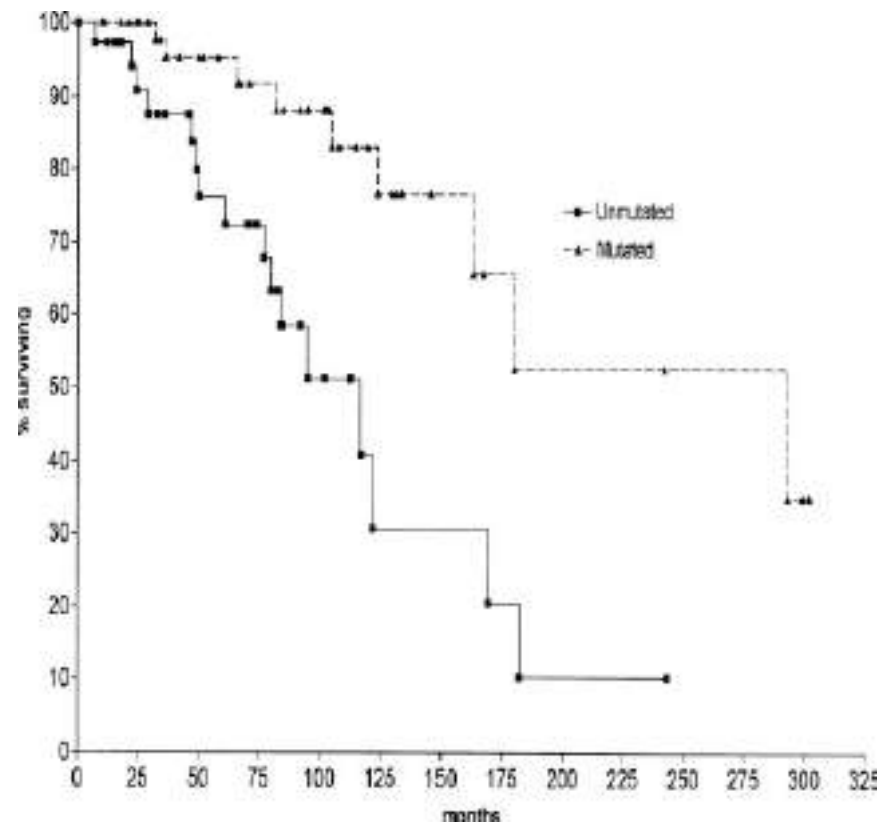


Molecular diagnostics

- BCR (IGHV) sequencing:
- Mutated (<98% identity with the germline configuration) (50 -70 %)
- Unmutated (>98% identity with the germline configuration) (30 -50%).
- Stereotyped subsets
- Cytogenetics/FISH
- Sequencing/NGS



Damle et al Blood 1999



Hamblin et al Blood 1999

Result summary: W299	Productive IGH rearranged sequence (no stop codon and in-frame junction)		
V-GENE and allele	Homsap IGHV3-72*01 F	score = 1299	identity = 93.54% (275/294 nt)
J-GENE and allele	Homsap IGHJ3*01 F	score = 205	identity = 90.00% (45/50 nt)
D-GENE and allele by IMGT/JunctionAnalysis	Homsap IGHD2-2*01 F	D-REGION is in reading frame 2	
FR-IMGT lengths, CDR-IMGT lengths and AA JUNCTION	[25.17.38.11]	[8.10.17]	CAKVSGCSSIGCYGLDAW
JUNCTION length (in nt) and decryption	57 nt = (10)-1{7}-6(22)-3{7}-8(11)	(3'V)3'(N)15'(D)3'(N)2)5'(5'J)	

Result summary: W86	Productive IGH rearranged sequence (no stop codon and in-frame junction)		
V-GENE and allele	Homsap IGHV5-10-1*03 F	score = 1440	identity = 100.00% (288/288 nt)
J-GENE and allele	Homsap IGHJ4*02 F	score = 195	identity = 89.58% (43/48 nt)
D-GENE and allele by IMGT/JunctionAnalysis	Homsap IGHD6-19*01 F	D-REGION is in reading frame 3	
FR-IMGT lengths, CDR-IMGT lengths and AA JUNCTION	[25.17.38.11]	[8.8.14]	CAREQWLGPNSPFDYW
JUNCTION length (in nt) and decryption	48 nt = (9)0{3}-8(13)0{11}-5(12)	(3'V)3'(N)15'(D)3'(N)2)5'(5'J)	

KEY POINTS

- In a series of 29 856 CLL patients, the incidence of BcR stereotypy peaked at 41%.
- Higher-order relations exist between stereotyped subsets, particularly for those from U-CLL, for which satellite subsets were identified.

Chronic lymphocytic leukemia (CLL) is characterized by the existence of subsets of patients with (quasi)identical, stereotyped B-cell receptor (BcR) immunoglobulins. Patients in certain major stereotyped subsets often display remarkably consistent clinicobiological profiles, suggesting that the study of BcR immunoglobulin stereotypy in CLL has important implications for understanding disease pathophysiology and refining clinical decision-making. Nevertheless, several issues remain open, especially pertaining to the actual frequency of BcR immunoglobulin stereotypy and major subsets, as well as the existence of higher-order connections between individual subsets. To address these issues, we investigated clonotypic IGHV-IGHD-IGHJ gene rearrangements in a series of 29 856 patients with CLL, by far the largest series worldwide. We report that the stereotyped fraction of CLL peaks at 41% of the entire cohort and that all 19 previously identified major subsets retained their relative size and ranking, while 10 new ones emerged; overall, major stereotyped subsets had a cumulative frequency of 13.5%. Higher-level

relationships were evident between subsets, particularly for major stereotyped subsets with unmutated IGHV genes (U-CLL), for which close relations with other subsets, termed "satellites," were identified. Satellite subsets accounted for 3% of the entire cohort. These results confirm our previous notion that major subsets can be robustly identified and are consistent in relative size, hence representing distinct disease variants amenable to compartmentalized research with the potential of overcoming the pronounced heterogeneity of CLL. Furthermore, the existence of satellite subsets reveals a novel aspect of repertoire restriction with implications for refined molecular classification of CLL. (*Blood*. 2021;137(10):1365-1376)

Cytogenetics/FISH

Aberration(s)	Frequency	
	Mutated IGHV n = 132 (44% of cases)	Unmutated IGHV n = 168 (56% of cases)
Clonal aberrations	80%	84%
13q deletion*	65%	48%
Isolated 13q deletion*	50%	26%
Trisomy 12	15%	19%
11q deletion*	4%	27%
17p deletion*	3%	10%
17p or 11q deletion*	7%	35%

*Significant difference between cases with and without IGHV mutation.

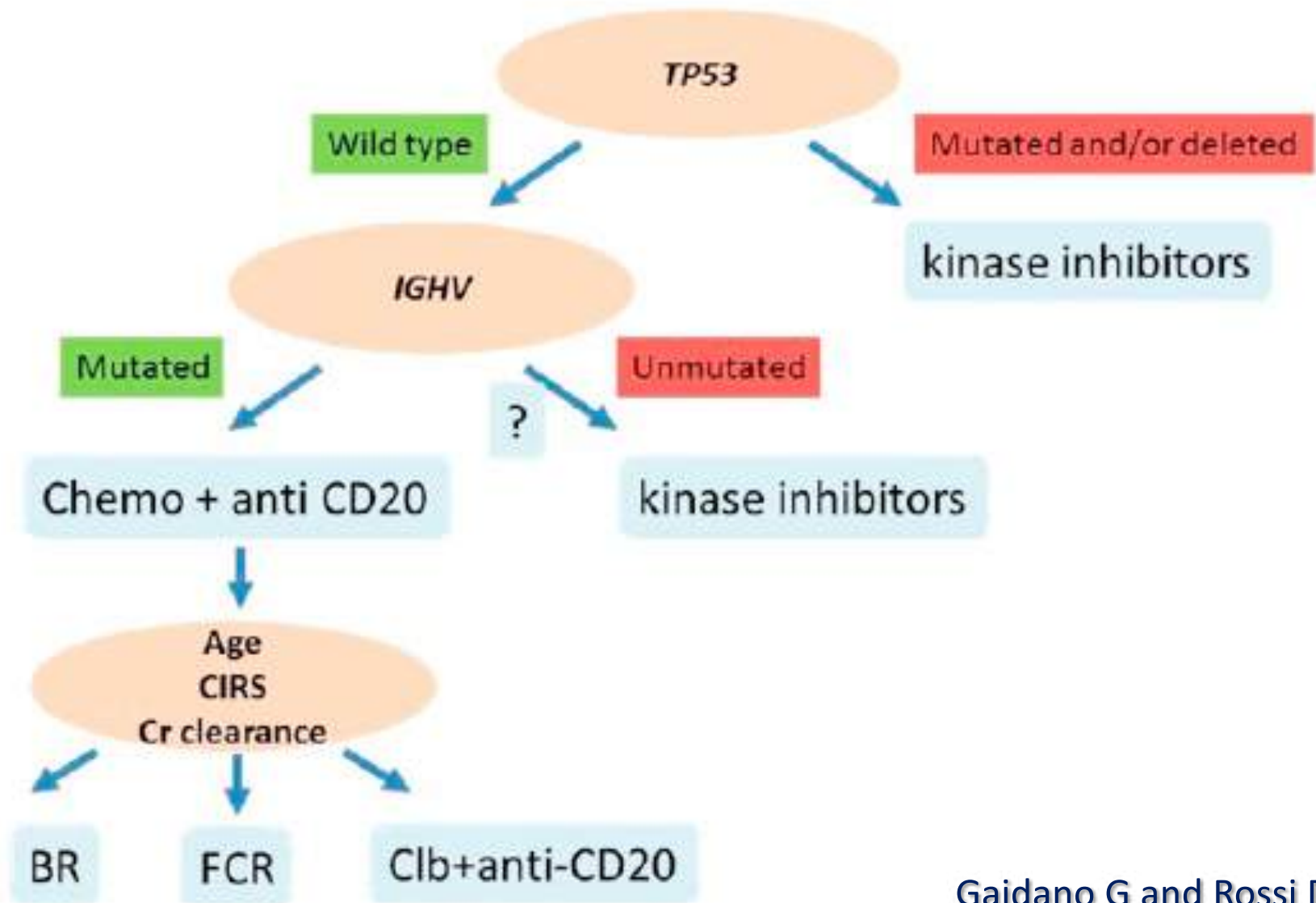


Gaidano G and Rossi D

Integrated mutational and cytogenetic analysis identifies new prognostic subgroups in chronic lymphocytic leukemia

Davide Rossi,¹ Silvia Rasi,¹ Valeria Spina,¹ Alessio Bruscaggin,¹ Sara Monti,¹ Carmela Ciardullo,¹ Clara Deambrogi,¹ Hossein Khiabani,² Roberto Serra,³ Francesco Bertoni,⁴ Francesco Forconi,^{5,6} Luca Laurenti,⁷ Roberto Marasca,⁸ Michele Dal-Bo,⁹ Francesca Maria Rossi,⁹ Pietro Bulian,⁹ Josep Nomdedeu,¹⁰ Giovanni Del Poeta,¹¹ Valter Gattei,⁹ Laura Pasqualucci,¹²⁻¹⁴ Raul Rabadan,² *Robin Foà,¹⁵ *Riccardo Dalla-Favera,^{12,13,16} and *Gianluca Gaidano¹

(*Blood*. 2013;121(8):1403-1412)



Gaidano G and Rossi D

Lymphoplasmacytic lymphoma

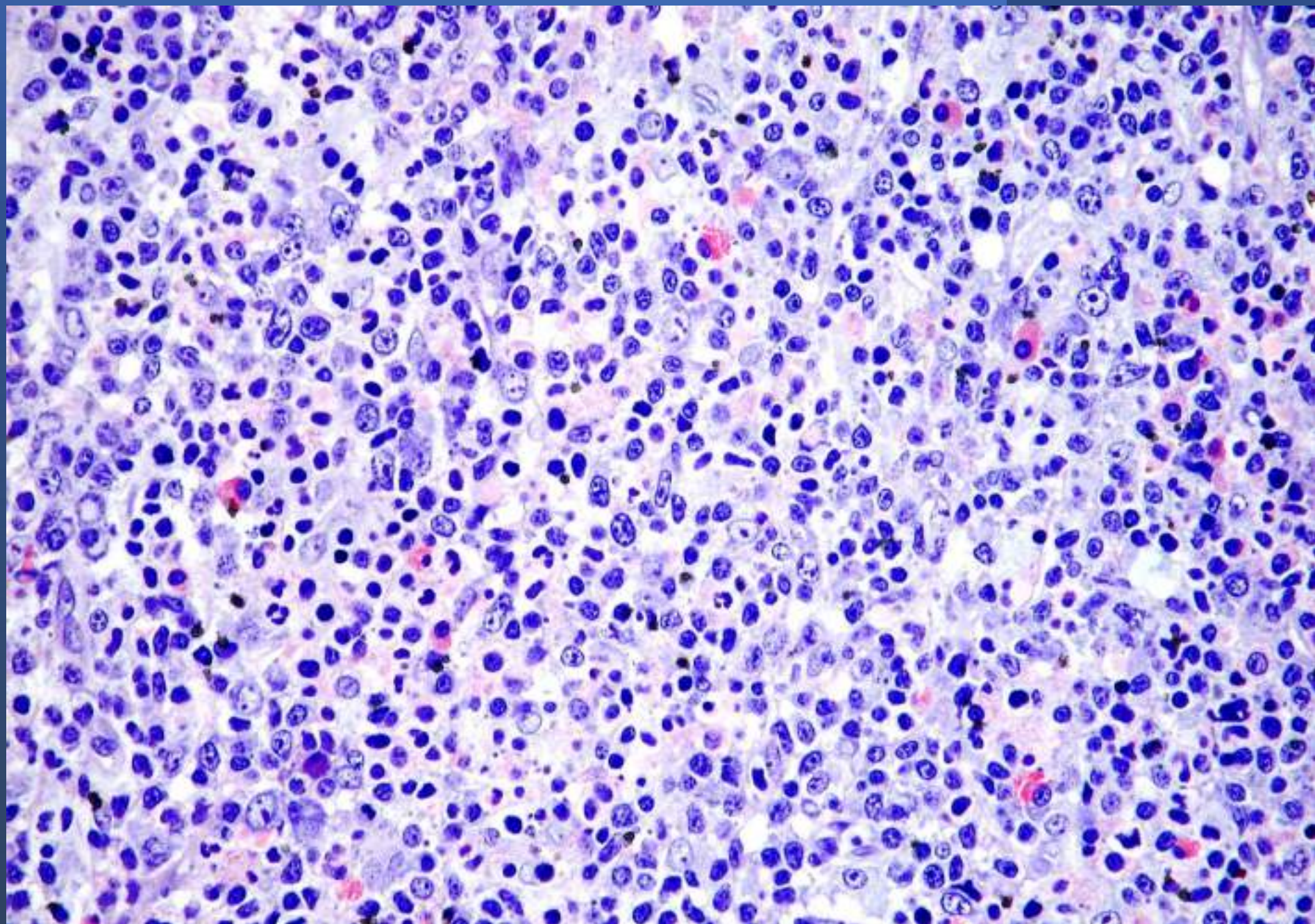
Small lymphocytes + plasmacytoid elements + plasma cells

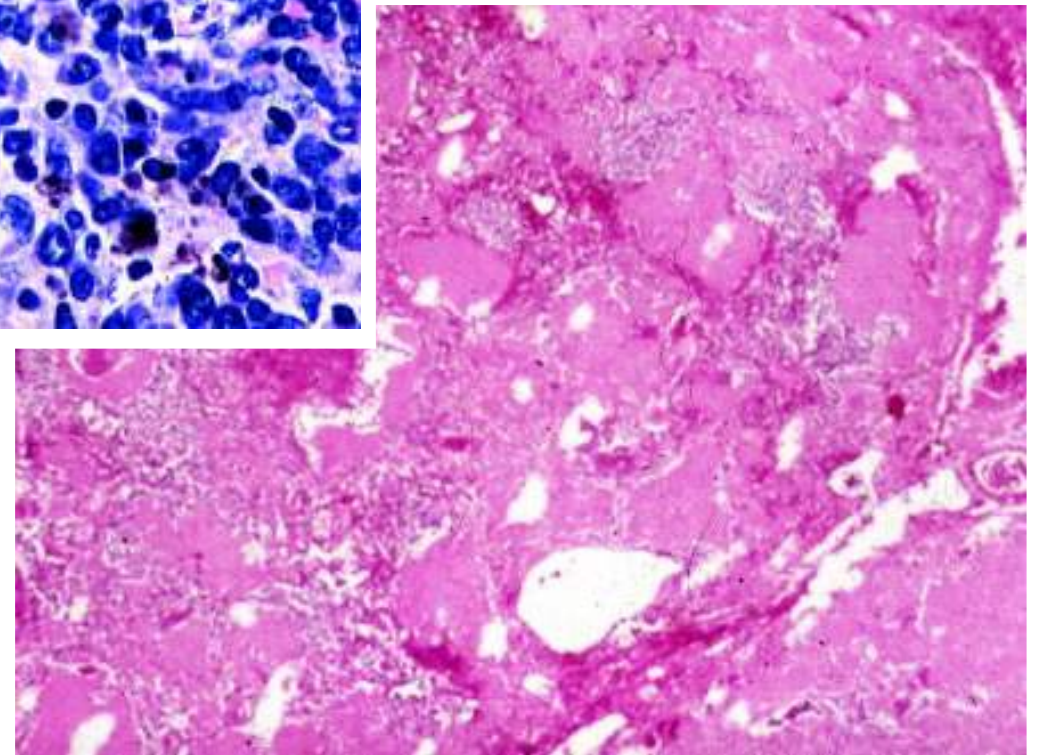
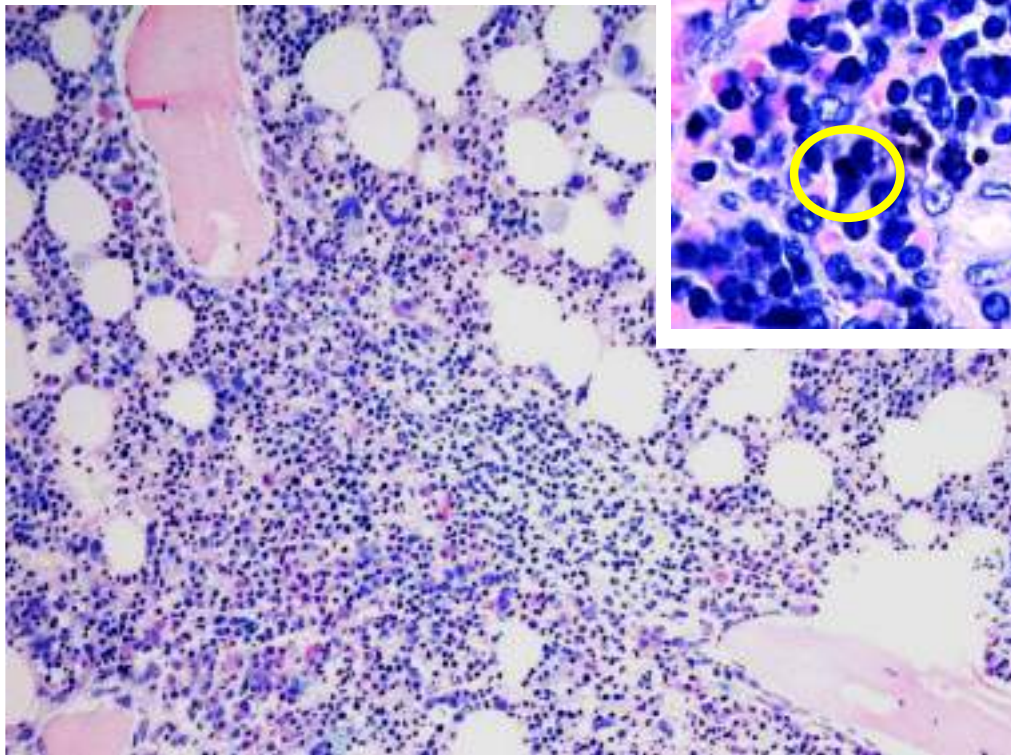
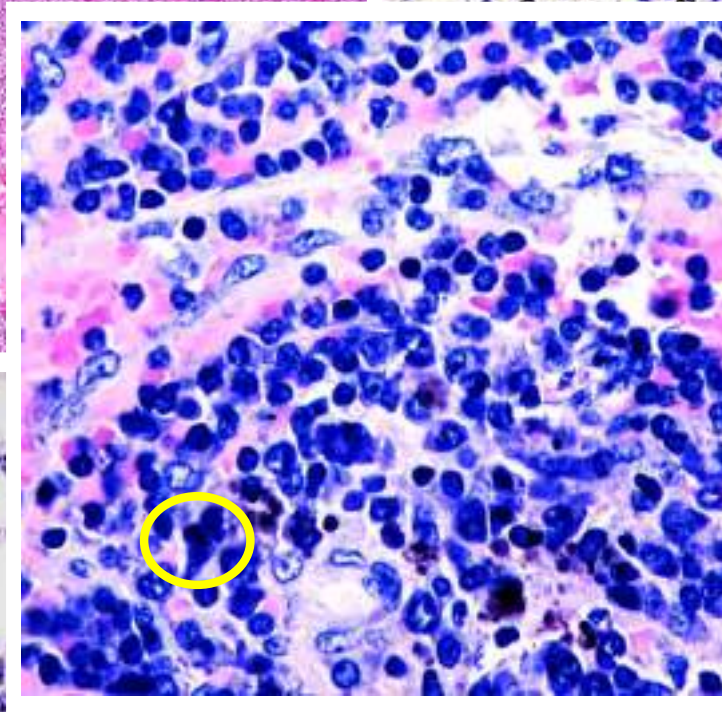
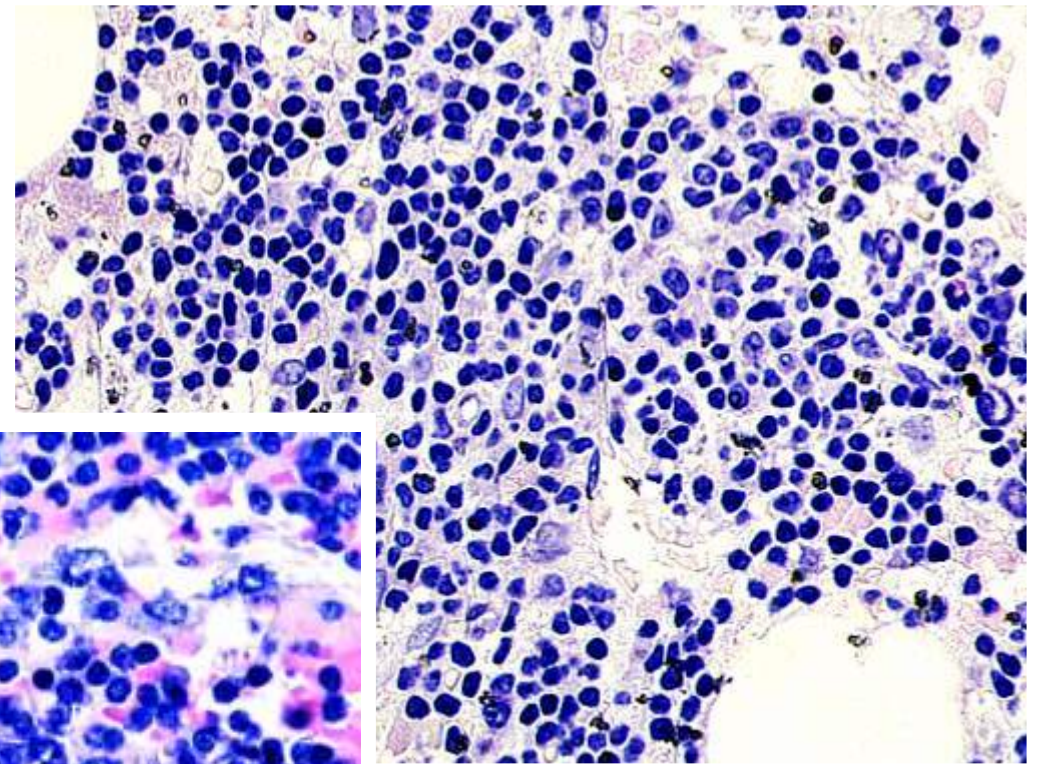
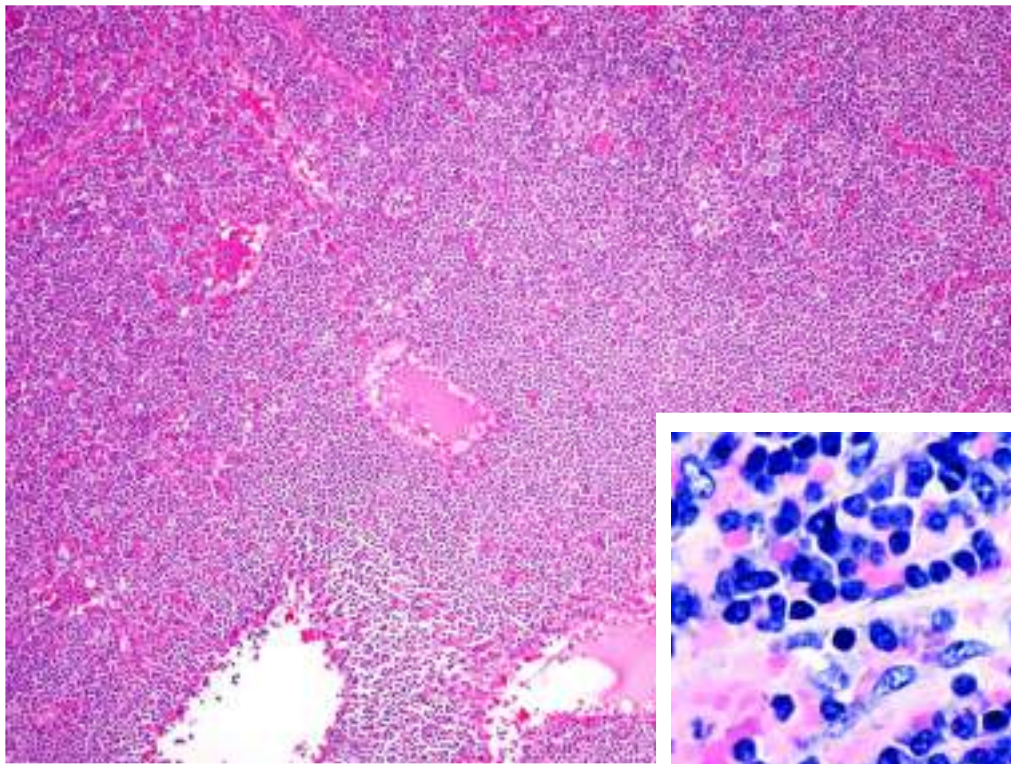
Exclusion diagnosis as other lymphomas can show plasmacellular differentiation

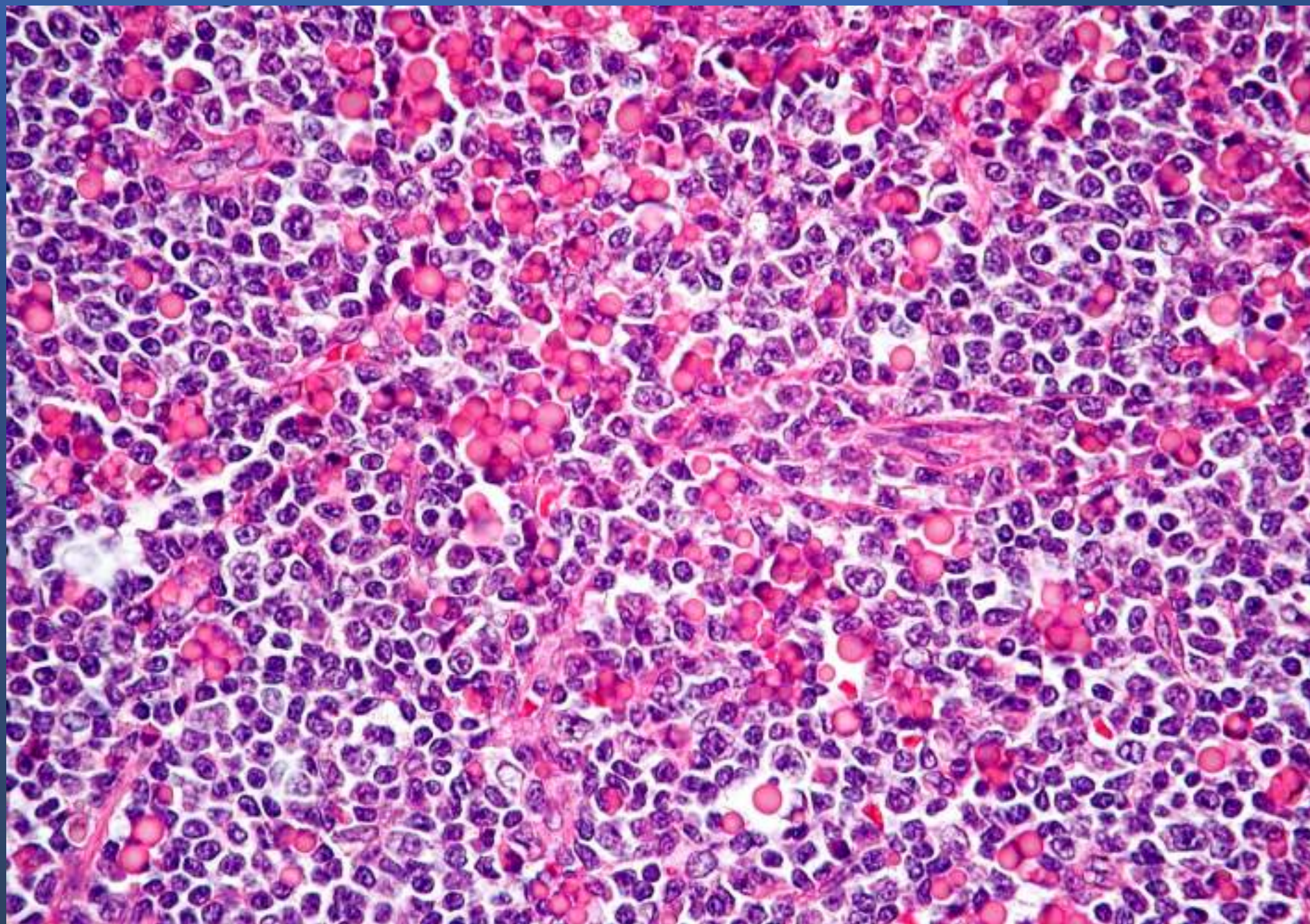
MYD88 L265P mutation characteristic but not exclusive

IgM paraprotein not necessarily required

WM found in a substantial subset, but not synonymous of LPL







Phenotype

CD19, CD20, CD22, CD79a, CD79b +

CD5 -

CD23 -/+

IgM+ (CYTOPLASMIC!)

IgD-

CD38+

IRF4 +/-

CD45 +/-

CD138 -

CD200 -

LEF1 -

Cyclin D1 -

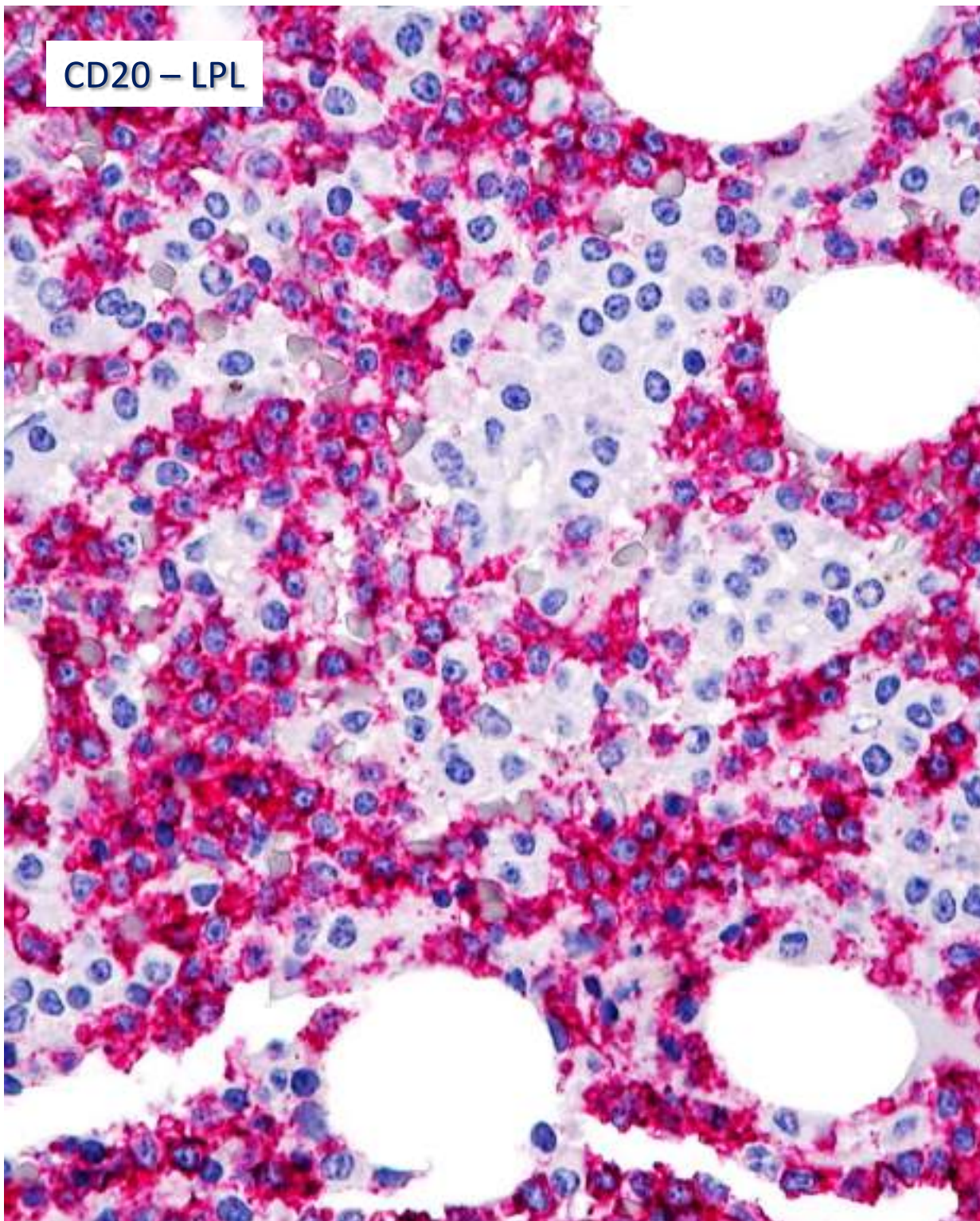
IRTA1, MNDA, T-bet -

CD10, BCL6, LMO2 -

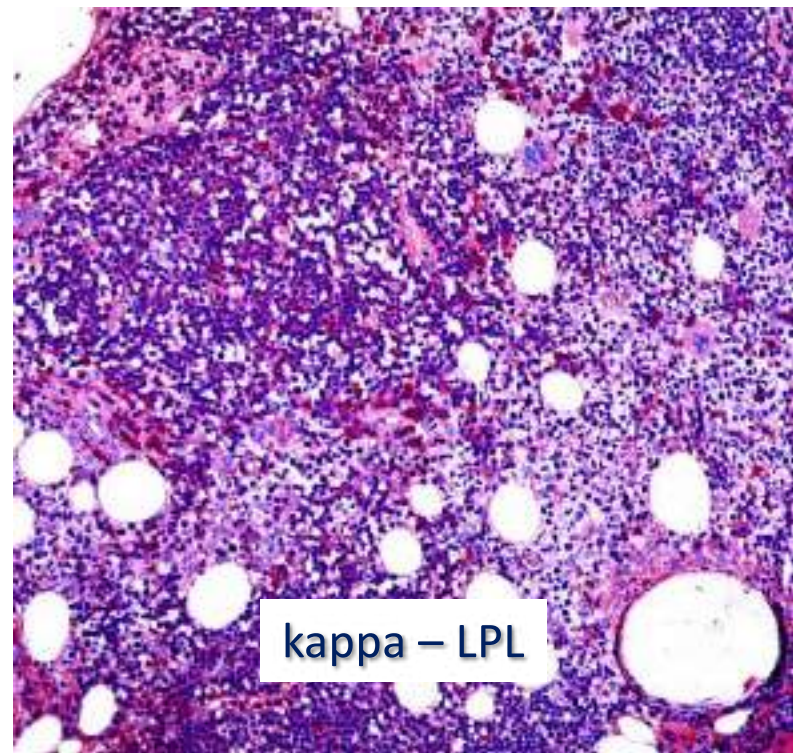
Ki-67: low



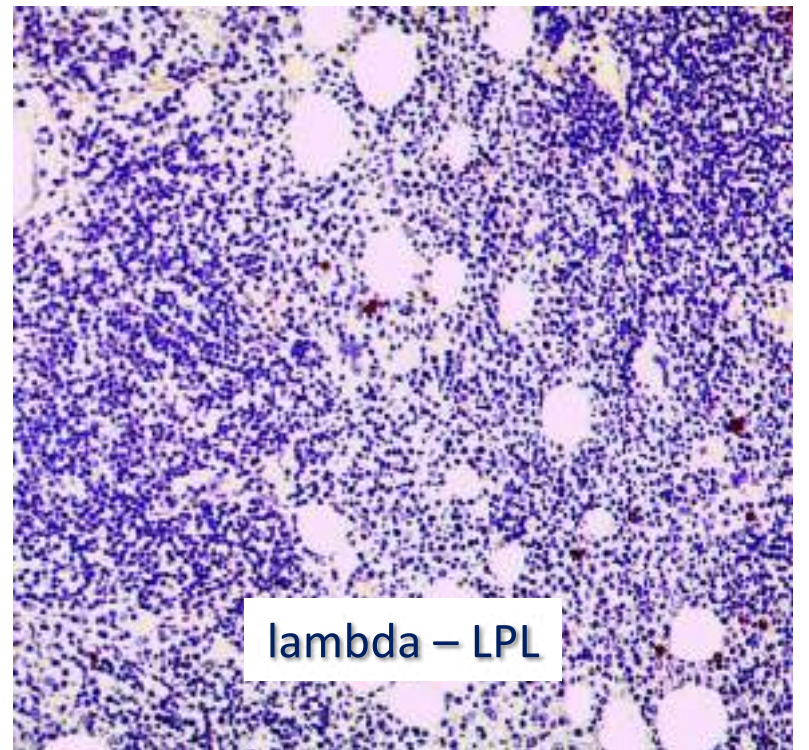
CD20 – LPL



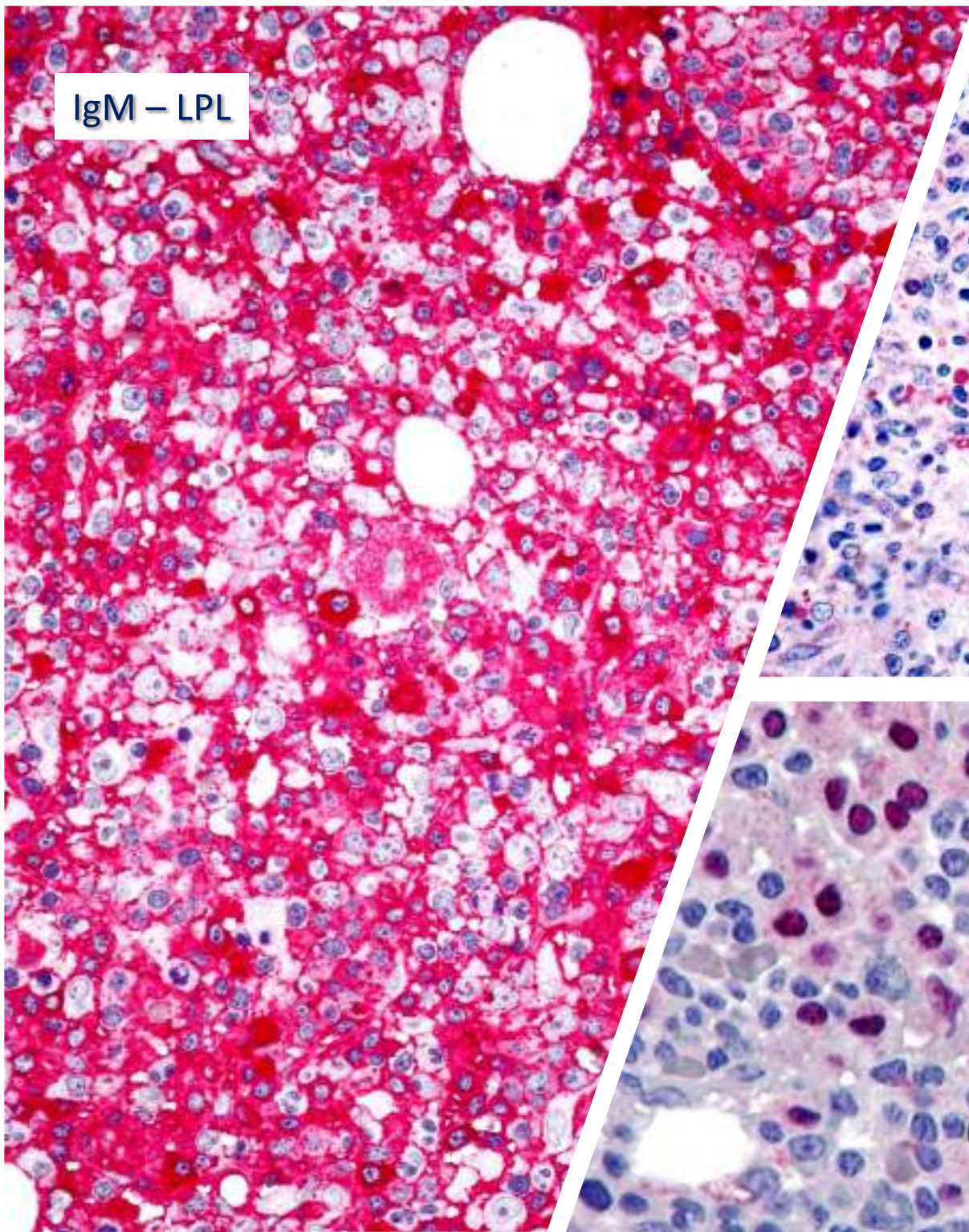
kappa – LPL



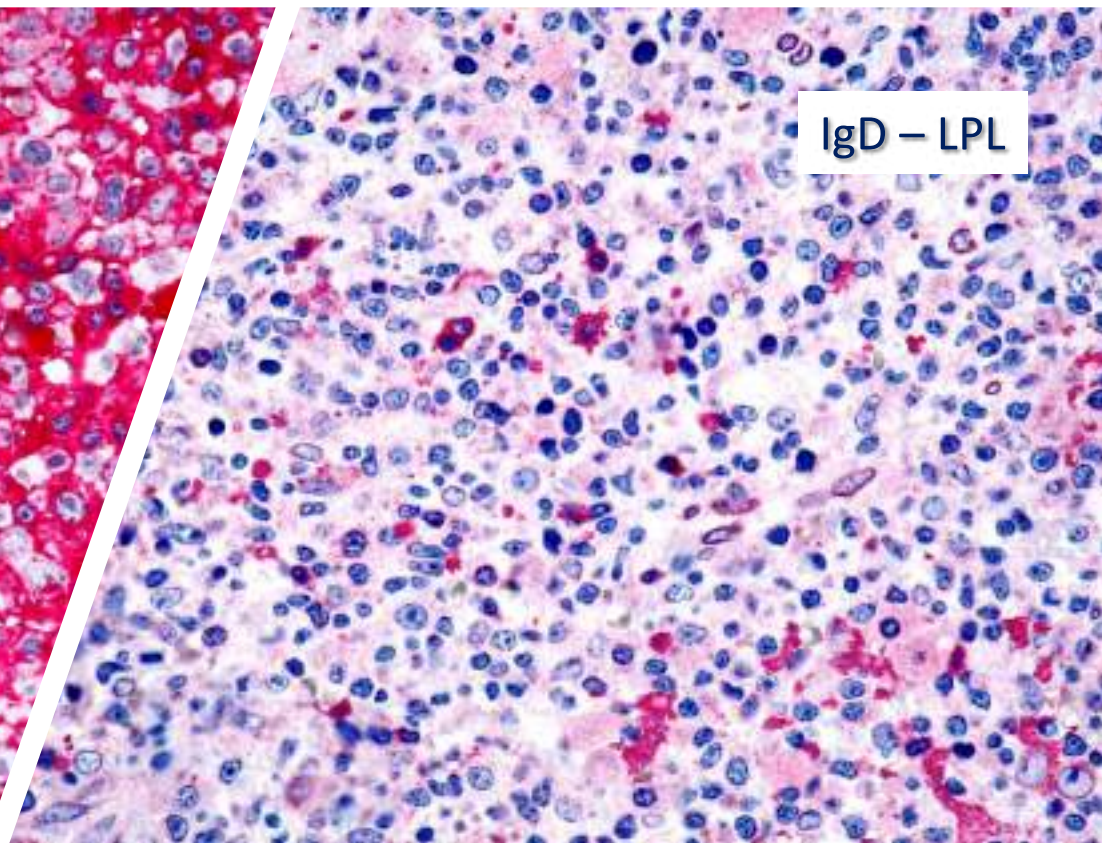
lambda – LPL



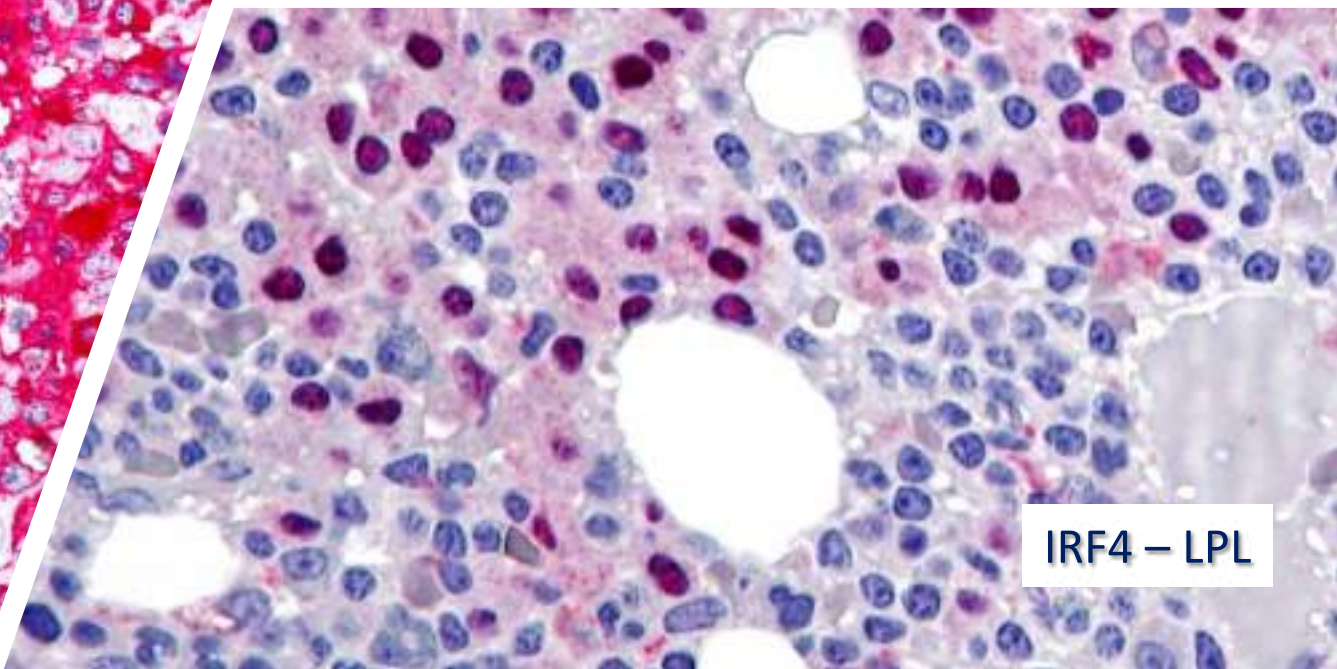
IgM - LPL



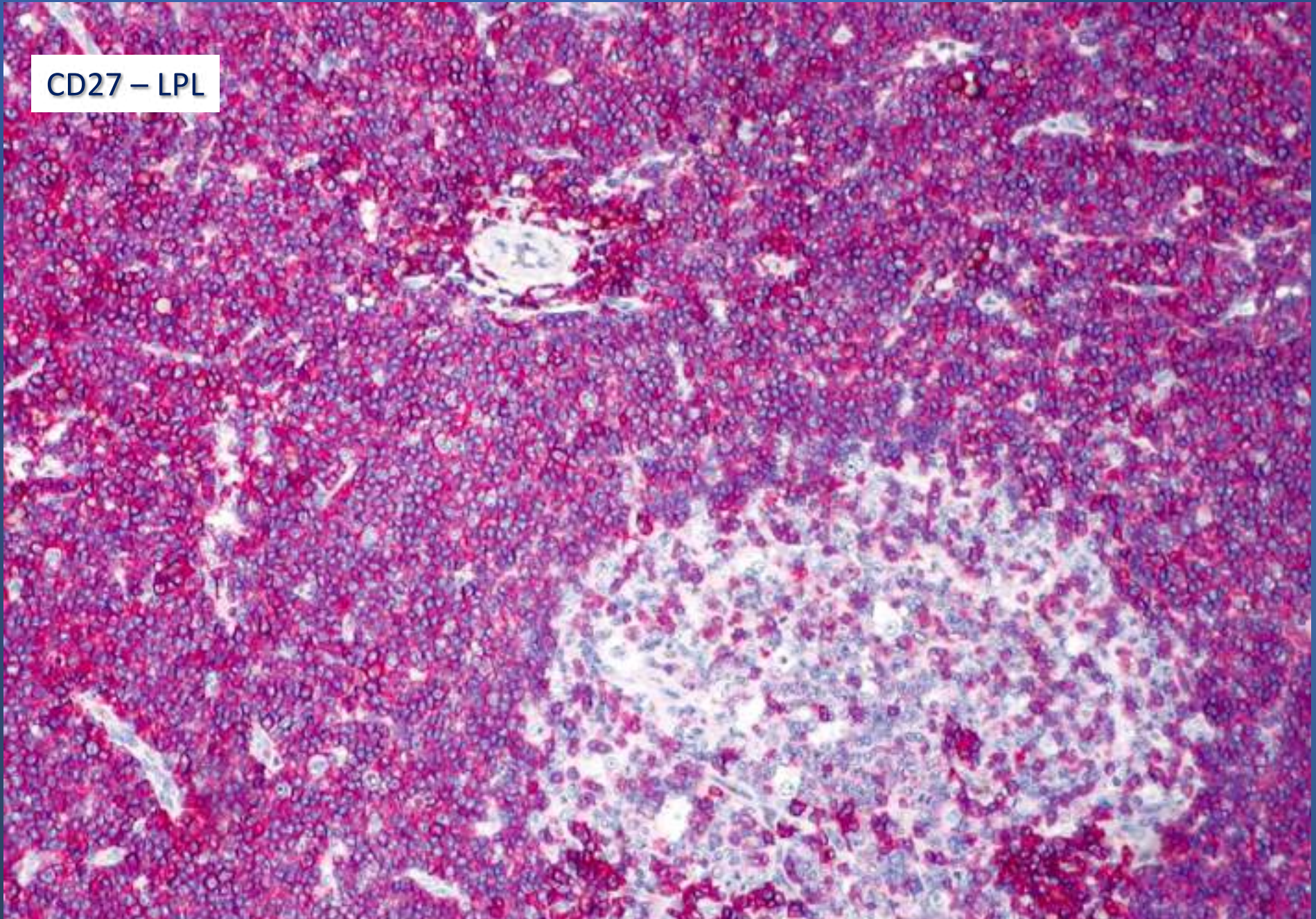
IgD - LPL

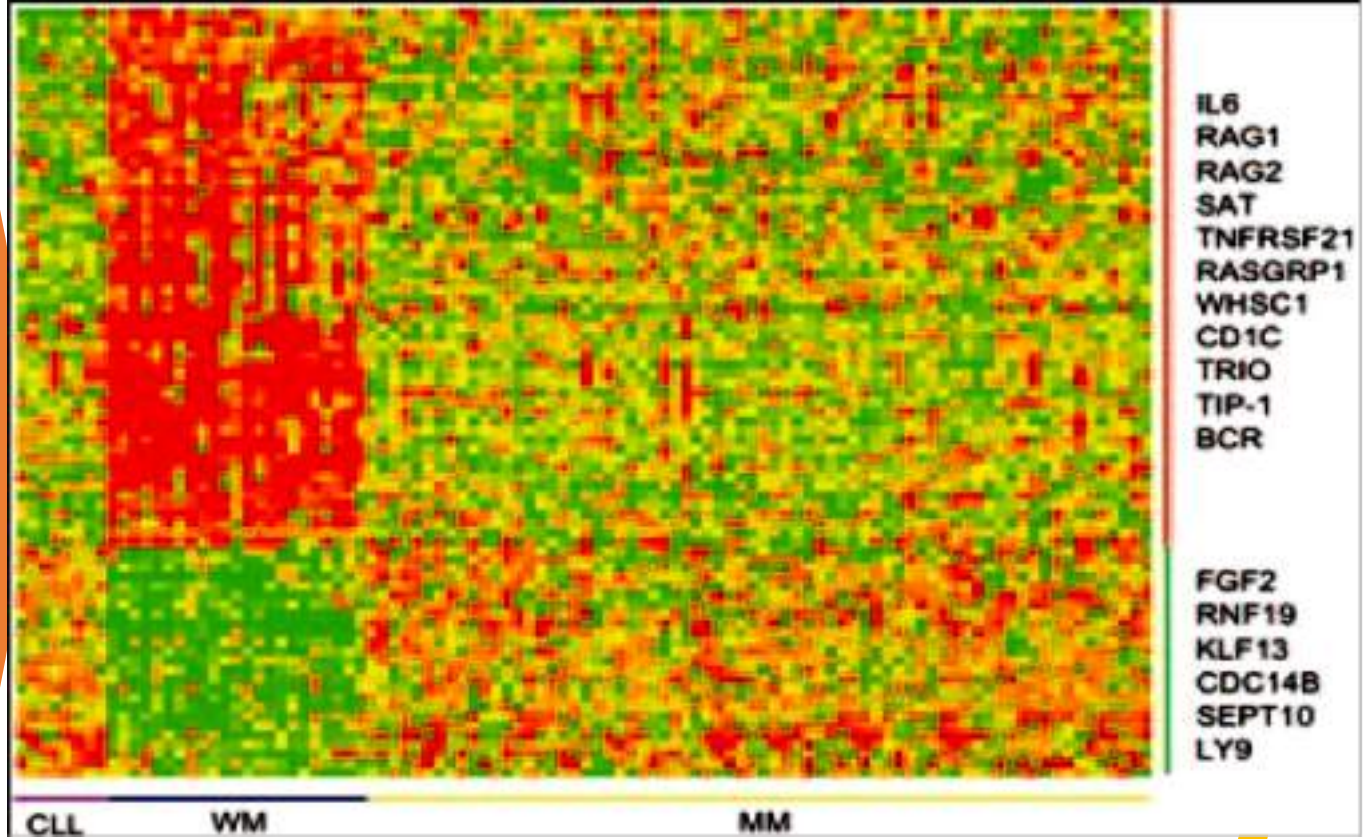


IRF4 - LPL



CD27 – LPL



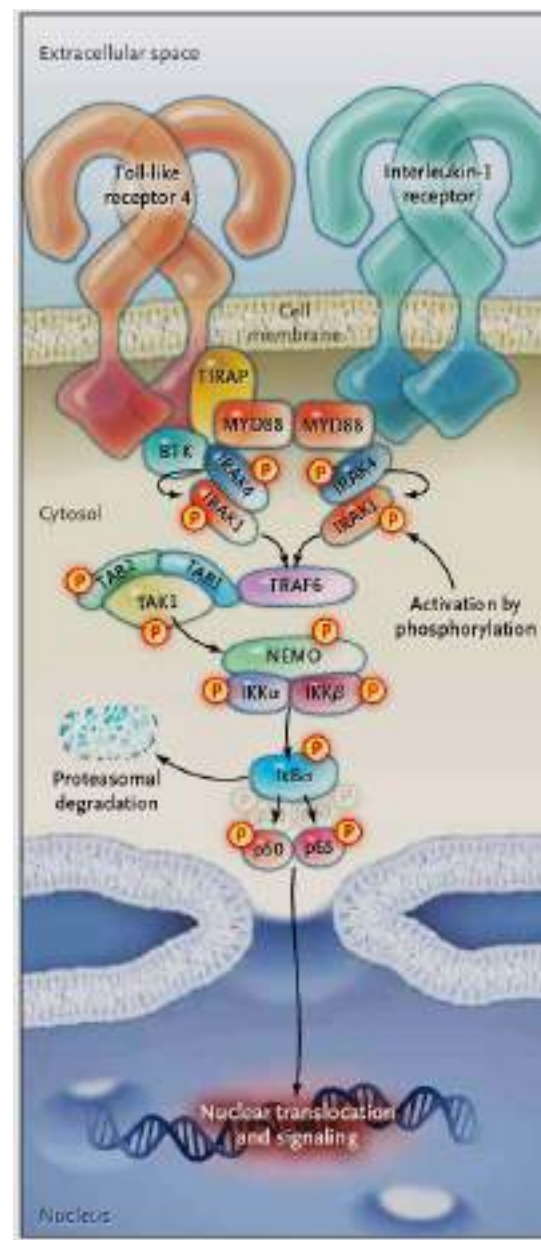


THE NEW ENGLAND JOURNAL of MEDICINE

ORIGINAL ARTICLE

MYD88 L265P Somatic Mutation in Waldenström's Macroglobulinemia

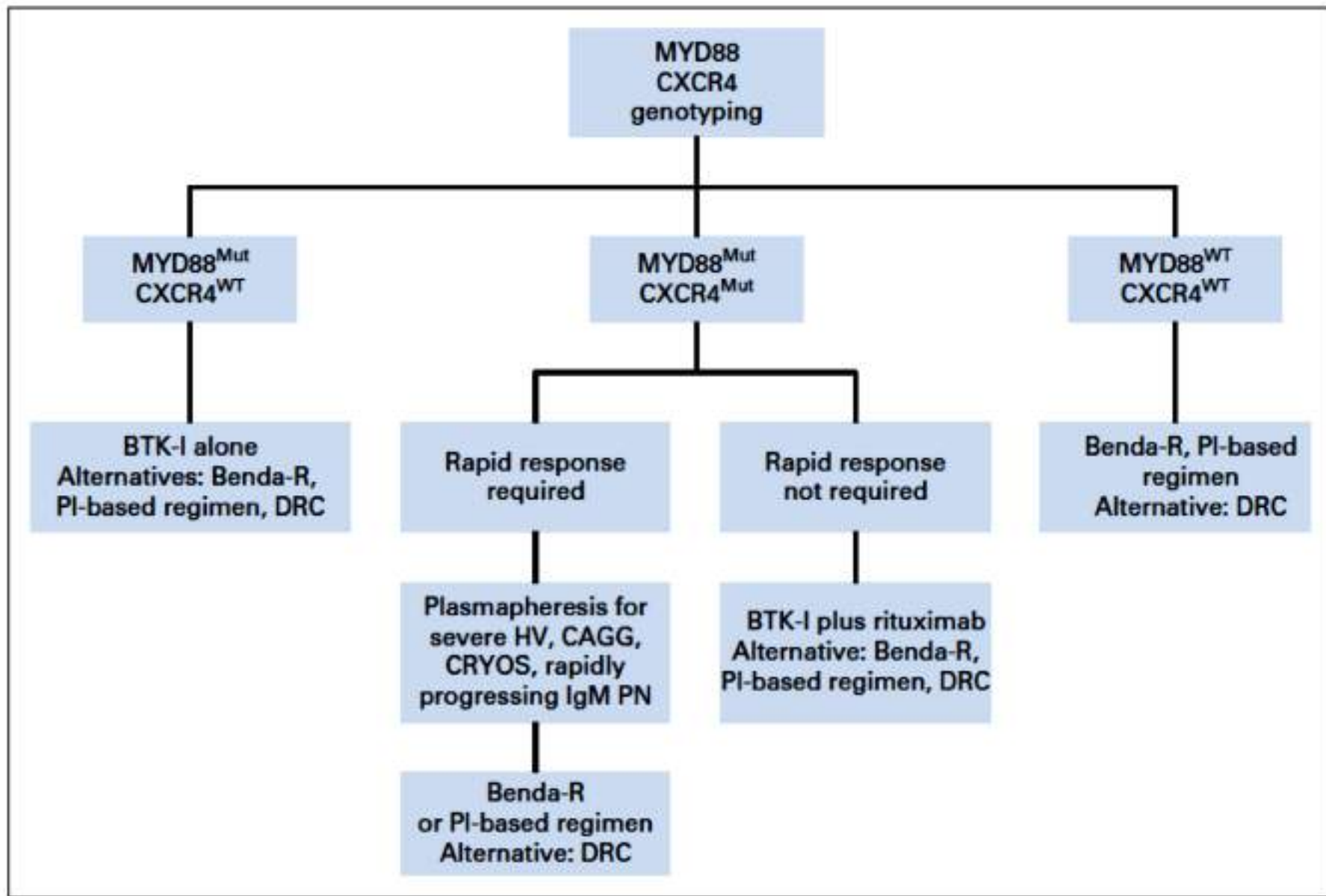
Steven P. Treon, M.D., Ph.D., Lian Xu, M.S., Guang Yang, Ph.D.,
Yangsheng Zhou, M.D., Ph.D., Xia Liu, M.D., Yang Cao, M.D.,
Patricia Sheehy, N.P., Robert J. Manning, B.S., Christopher J. Patterson, M.A.,
Christina Tripsas, M.A., Luca Arcaini, M.D., Geraldine S. Pinkus, M.D.,
Scott J. Rodig, M.D., Ph.D., Aliyah R. Sohani, M.D., Nancy Lee Harris, M.D.,
Jason M. Laramie, Ph.D., Donald A. Skifter, Ph.D., Stephen E. Lincoln, Ph.D.,
and Zachary R. Hunter, M.A.



Lymphoplasmacytic Lymphoma and Nodal Marginal Zone Lymphoma

- *MYD88* L265P can distinguish LPL (70-100%) from NMZL (0-20%)
 - Frequency in NMZL may be overstated. Re-review reveals many of the cases are LPL
- Who to test for *MYD88* L265P
 - Classic WM diagnosis, testing likely will add little
 - Small B-cell lymphoma with plasmacytic differentiation, where LPL and other small B-cell lymphomas are in the differential diagnosis should be tested
 - *CXCR4* mutation may illuminate cases negative for *MYD88*
 - Further gene mutations: *ARID1A*, *CD79B*

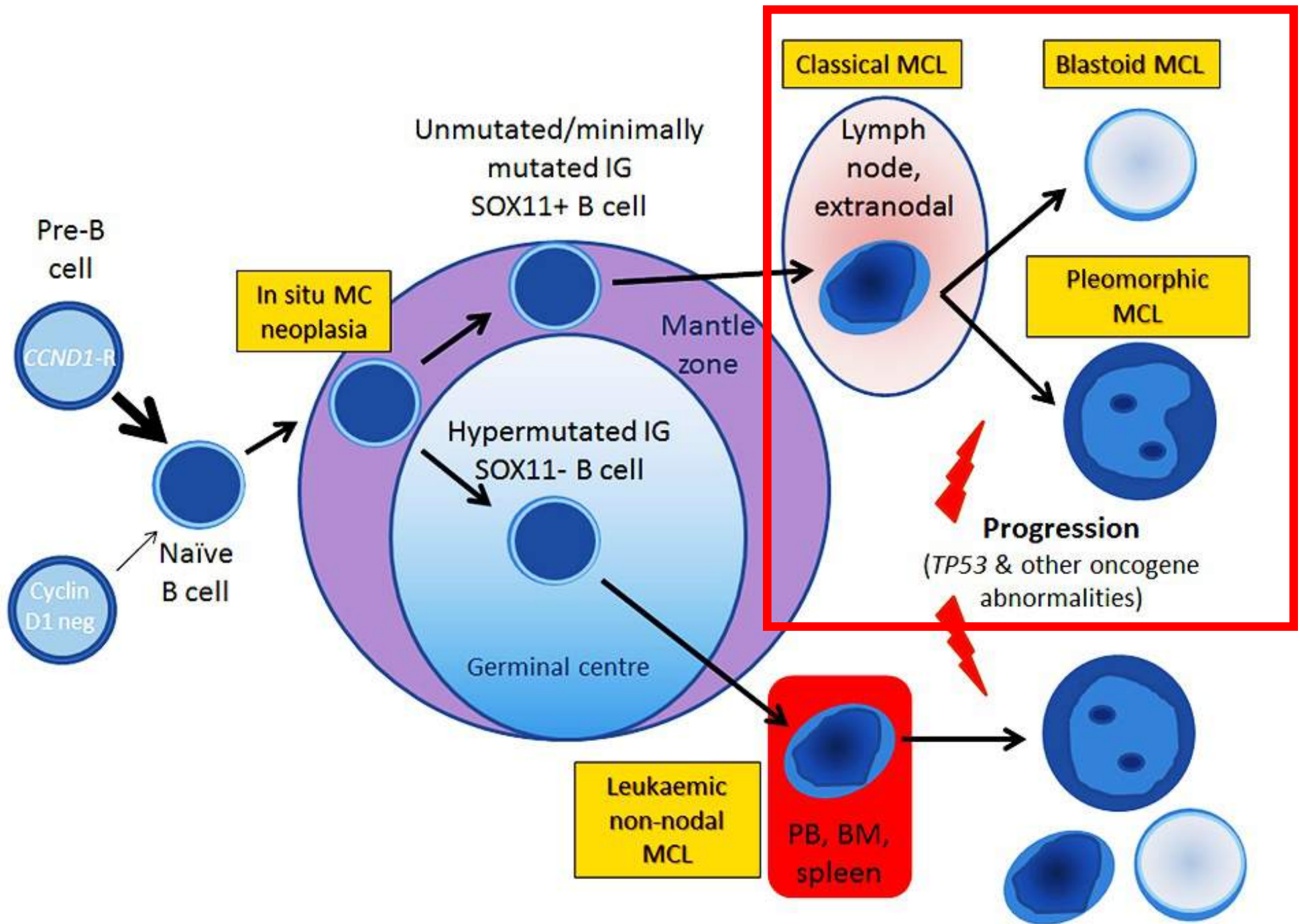


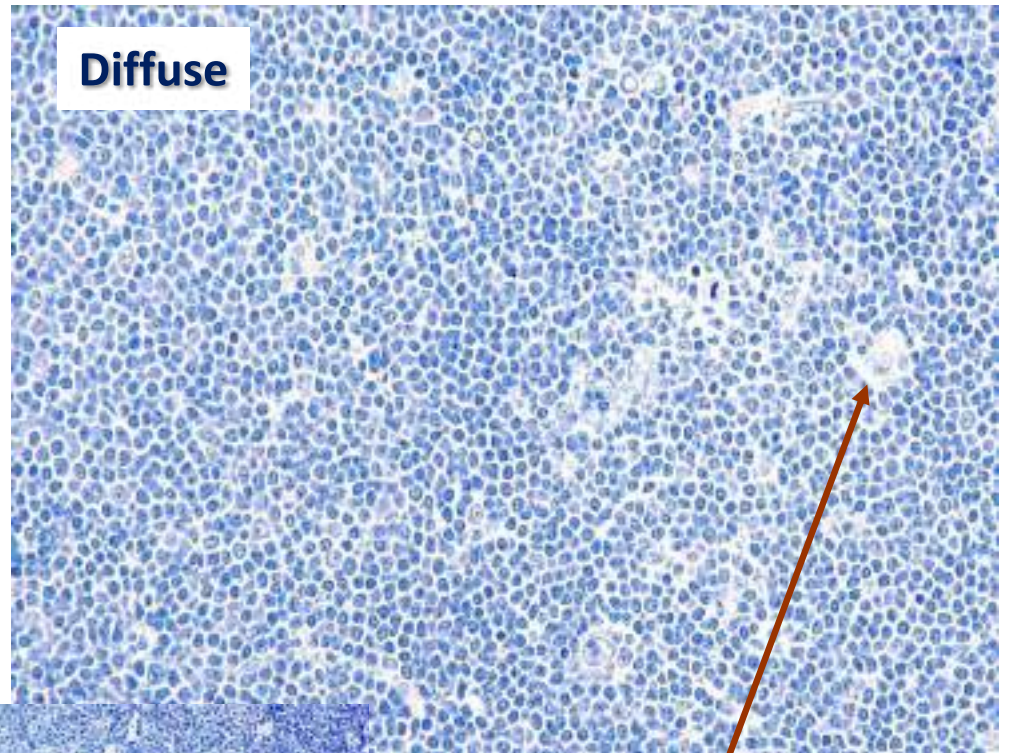
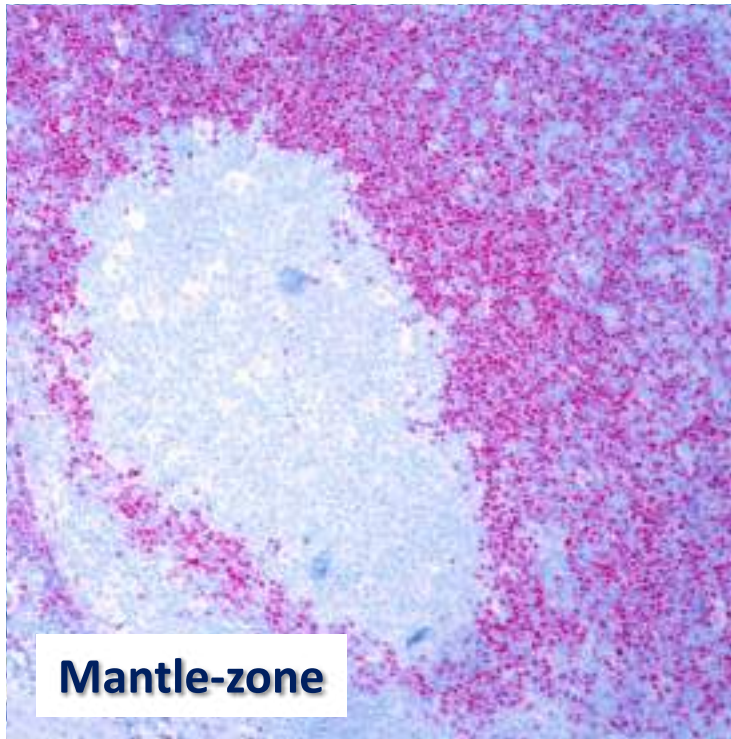


Mantle cell lymphoma

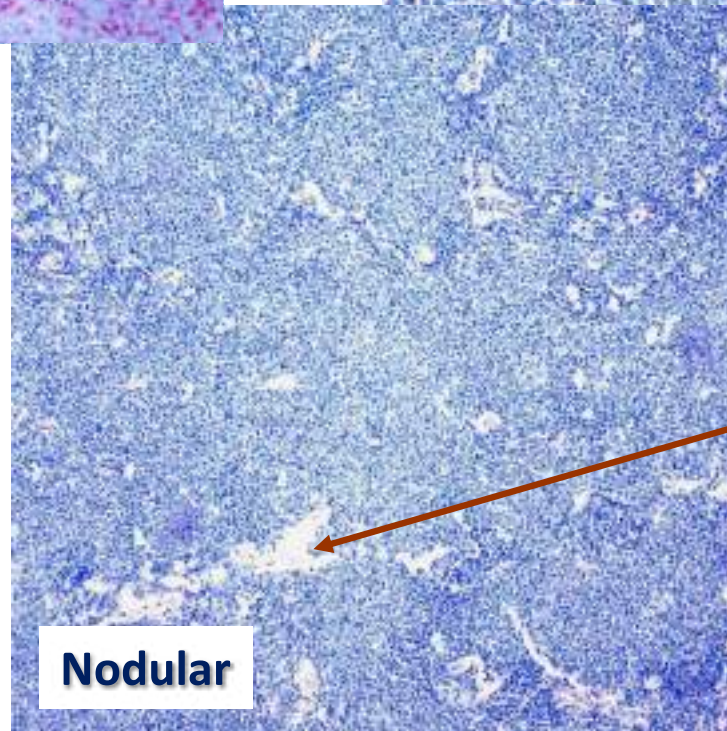
Definition

Mantle cell lymphoma is a mature B-cell neoplasm usually composed of monomorphic small to medium-sized lymphoid cells with irregular nuclear contours; in > 95% of cases, there is a *CCND1* translocation {245,543,2219,2269,3849,4018}. Neoplastic transformed cells (centroblasts), paraimmunoblasts, and proliferation centres are absent. Mantle cell lymphoma has traditionally been considered a very aggressive and incurable lymphoma, but more indolent variants, including leukaemic non-nodal mantle cell lymphoma and in situ mantle cell neoplasia, are now also well recognized.

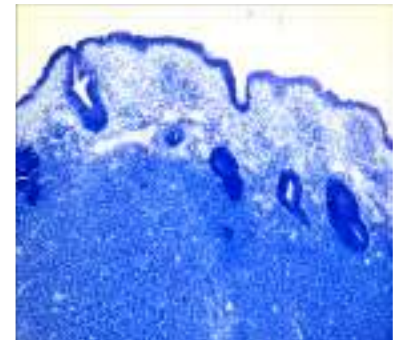




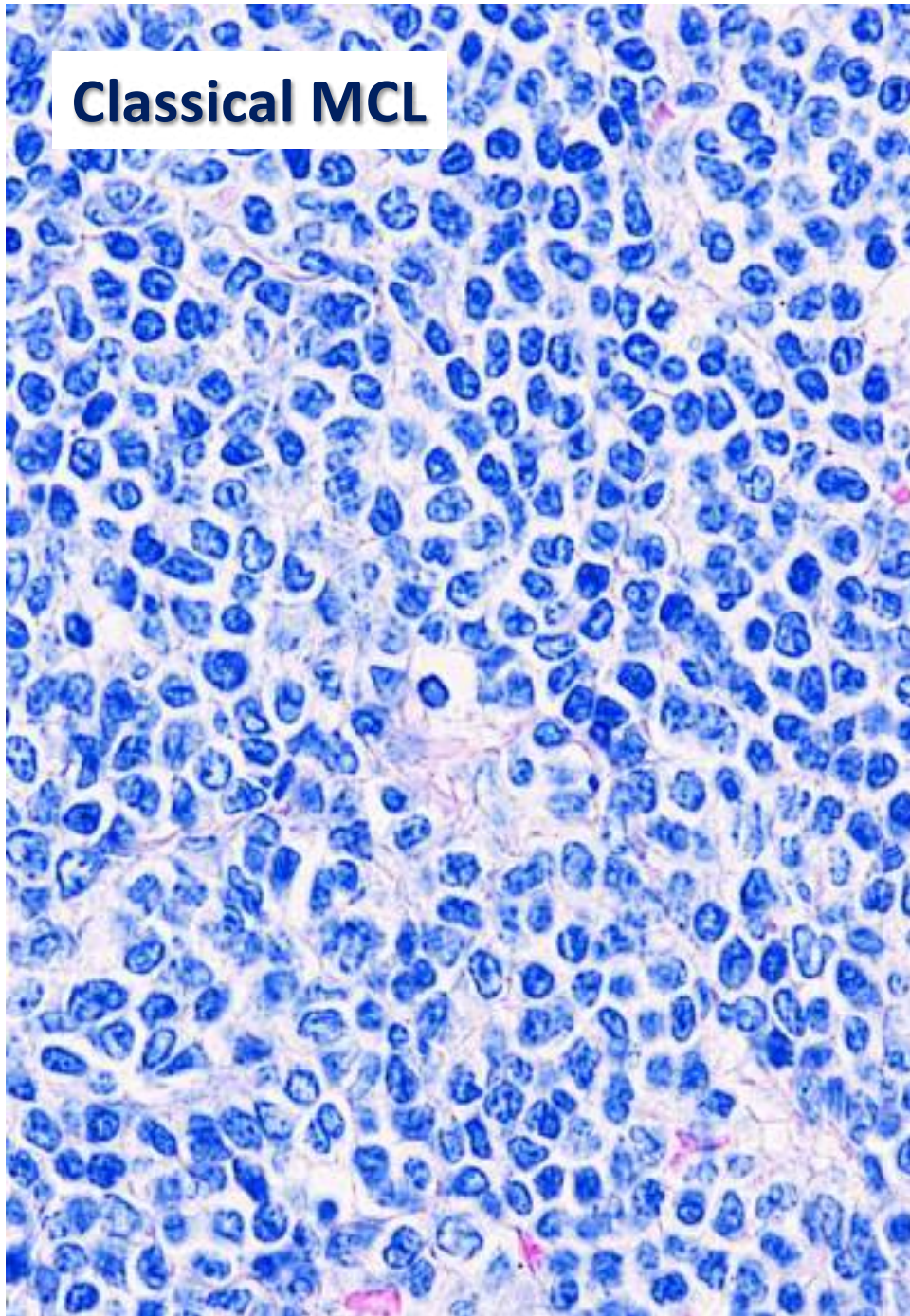
MCL Growth Patterns



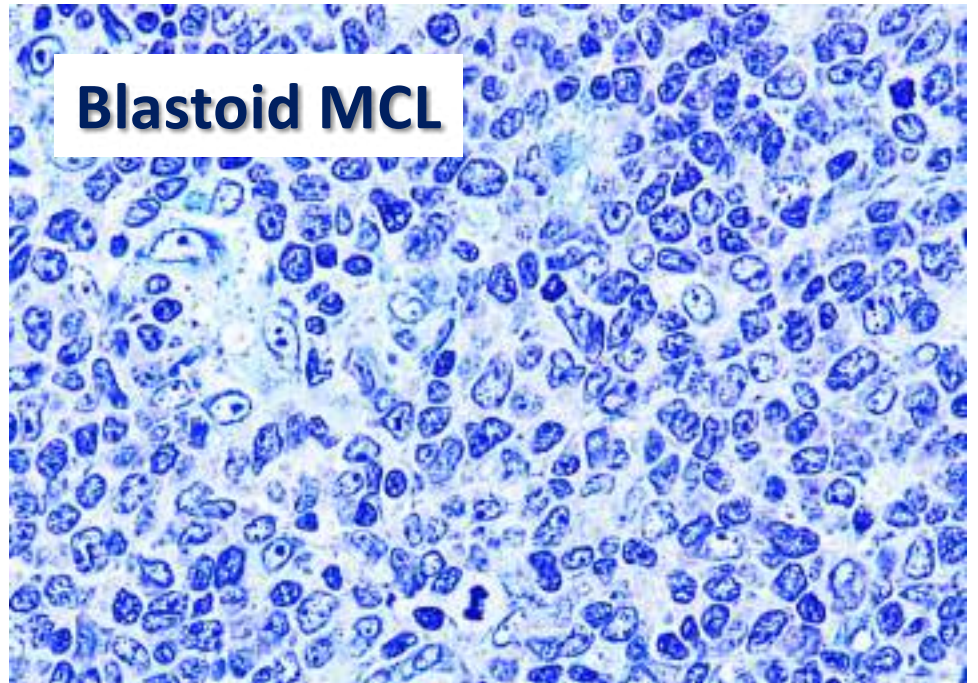
Epithelioid
histiocytes



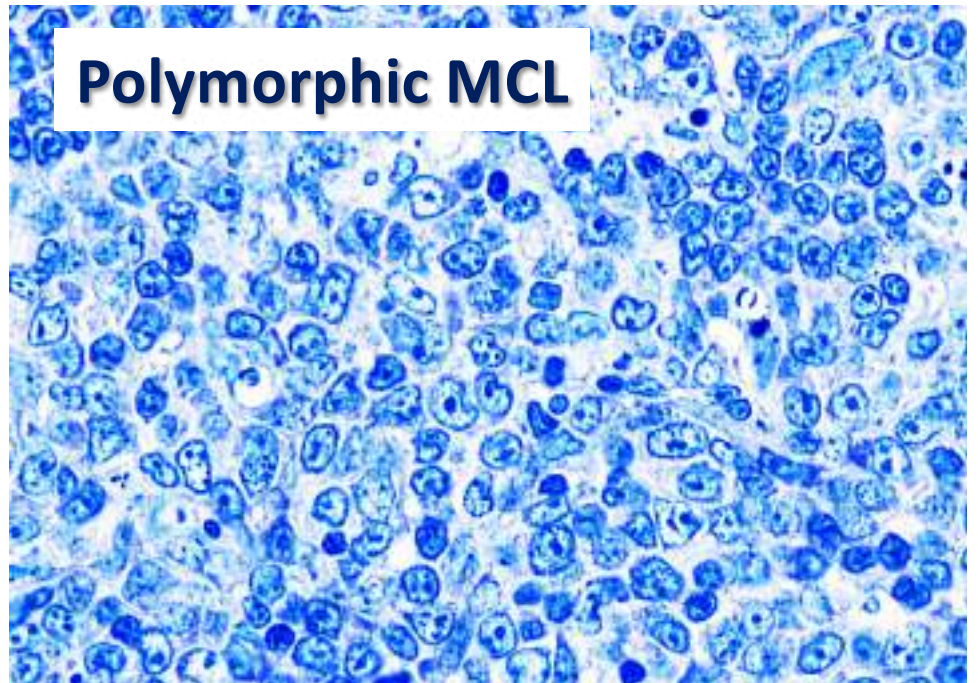
Classical MCL



Blastoid MCL



Polymorphic MCL



Phenotype

CD19, CD20, CD22, CD79a, CD79b +

CD5+

IgM+

IgD+

Cyclin D1+ (>95%)

SOX11+ (- in leukemic non nodal)

BCL2+

CD23 -

IRF4 -

CD200 – (at times + in leukemic non nodal)

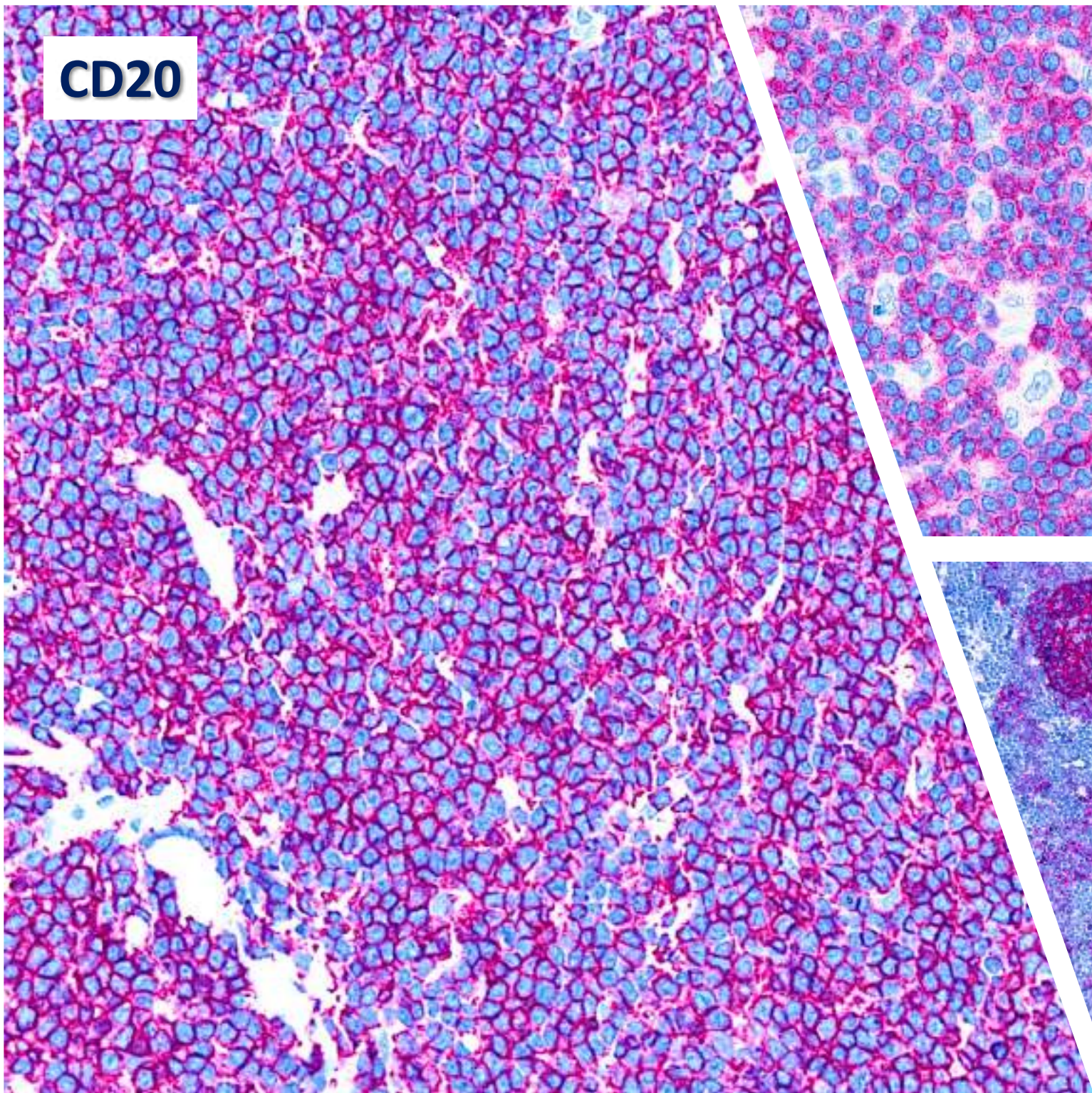
LEF1 – (at times + in blastoid/pleomorphic)

IRTA1, MNDA, T-bet -

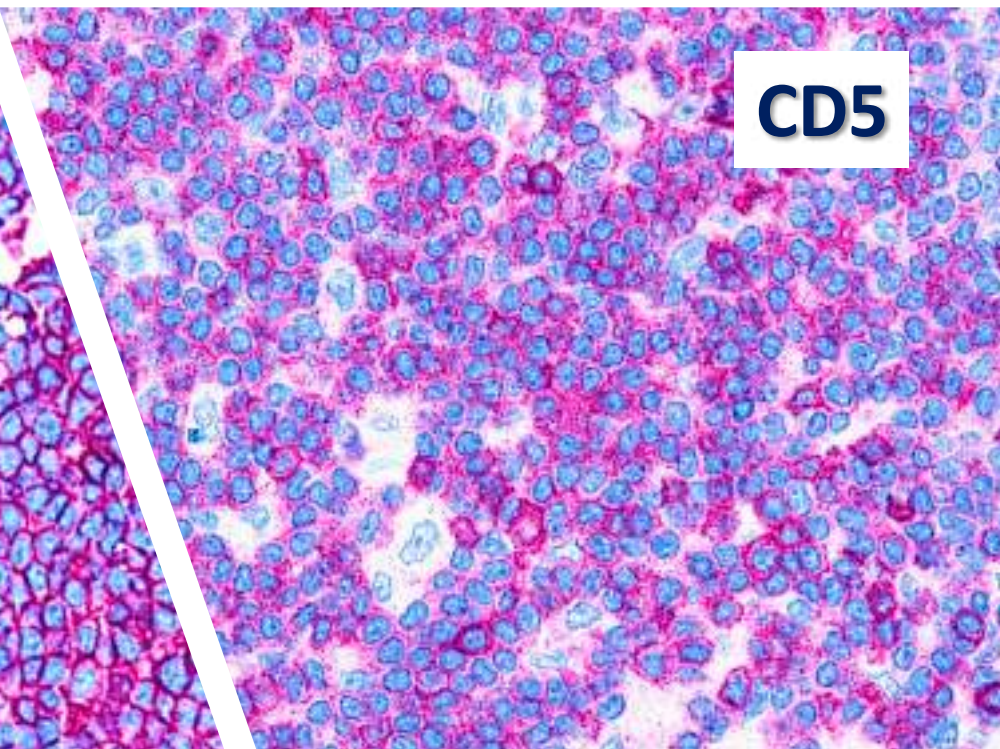
CD10, BCL6, LMO2 –

Ki-67: variable

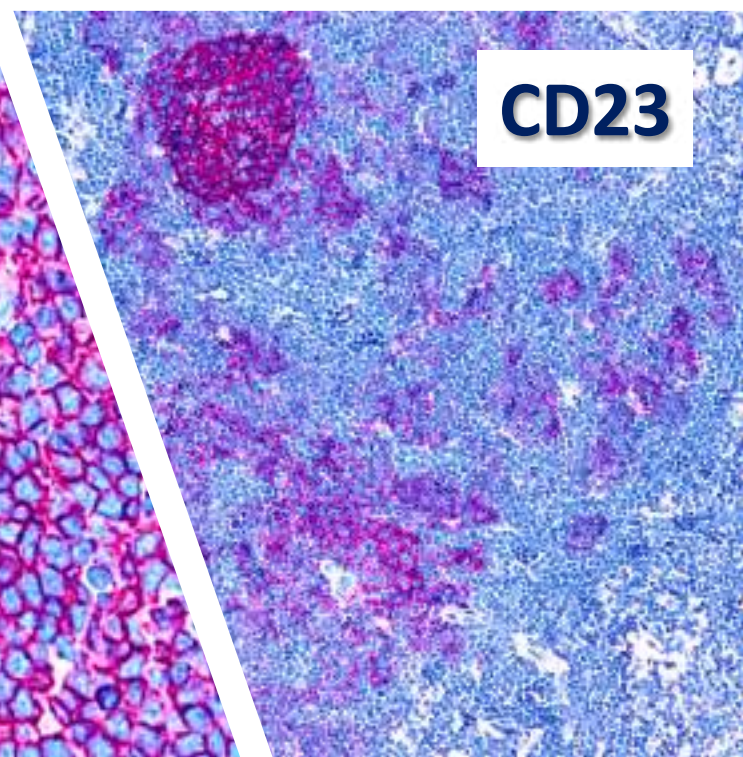
CD20



CD5















CD23



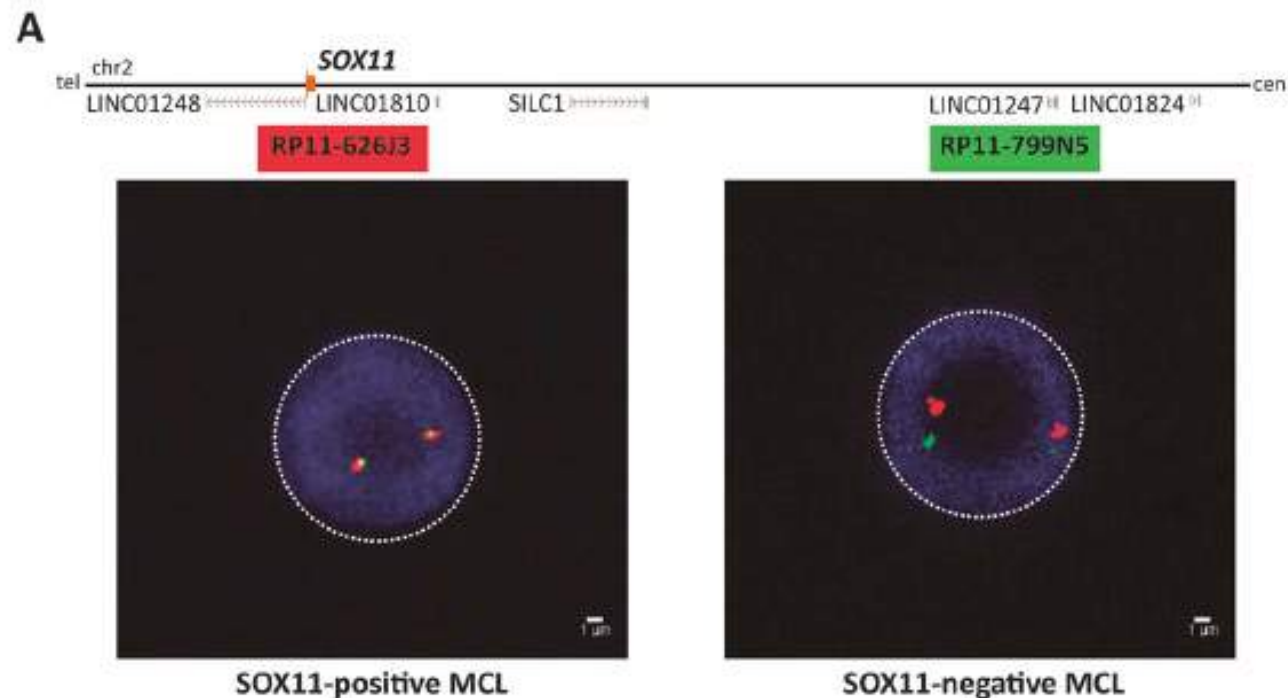
LYMPHOMA

Insights into the mechanisms underlying aberrant *SOX11* oncogene expression in mantle cell lymphoma

Roser Vilarrasa-Blasi ^{1,2}[✉], Núria Verdaguer-Dot¹, Laura Berver^{3,4}, Paula Soler-Vila⁵, Renée Beekman¹, Vicente Chapaprieta ¹, Marta Kulis¹, Ana C. Queirós¹, Maribel Parra ⁴, María José Calasanz ^{6,7}, Xabier Agirre ^{6,7}, Felipe Prosper ^{6,7,8}, Sílvia Beà^{1,2,7}, Dolors Colomer ^{1,2,7}, Marc A. Martí-Renom^{5,9}, Adolfo Ferrando ³, Elías Campo ^{1,2,7} and José Ignacio Martín-Subero ^{1,2,7,9}

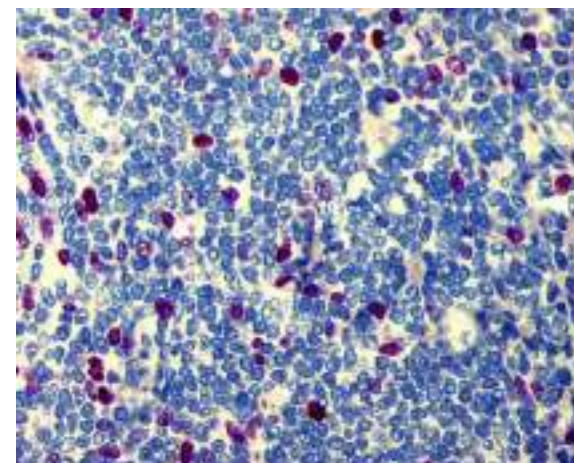
© The Author(s), under exclusive licence to Springer Nature Limited 2021

Leukemia (2022) 36:583–587; <https://doi.org/10.1038/s41375-021-01389-w>

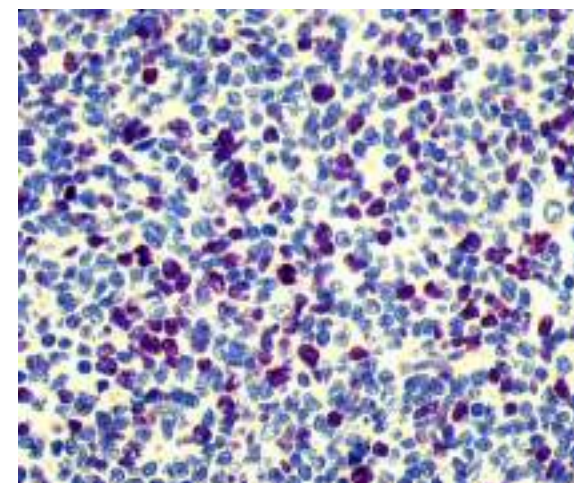
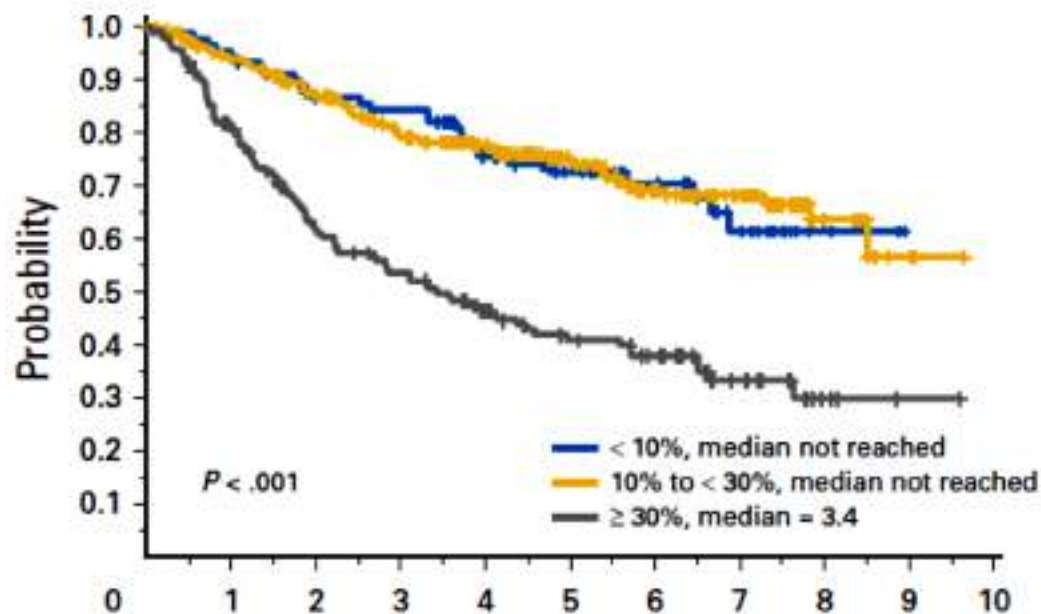


Prognostic Value of Ki-67 Index, Cytology, and Growth Pattern in Mantle-Cell Lymphoma: Results From Randomized Trials of the European Mantle Cell Lymphoma Network

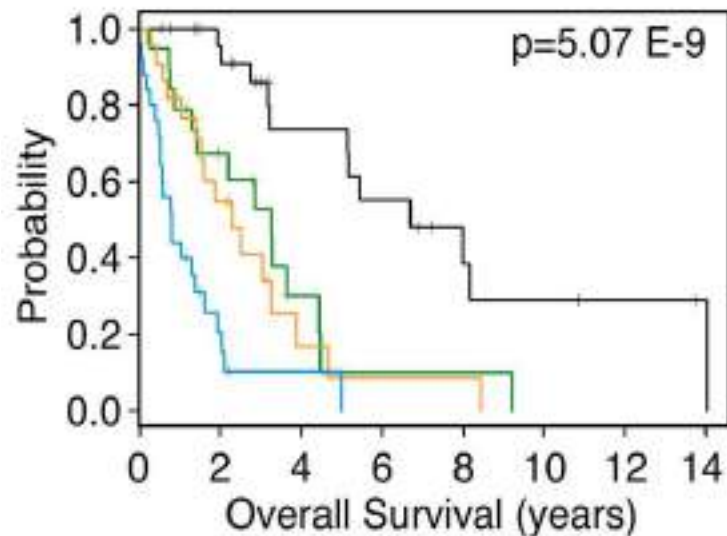
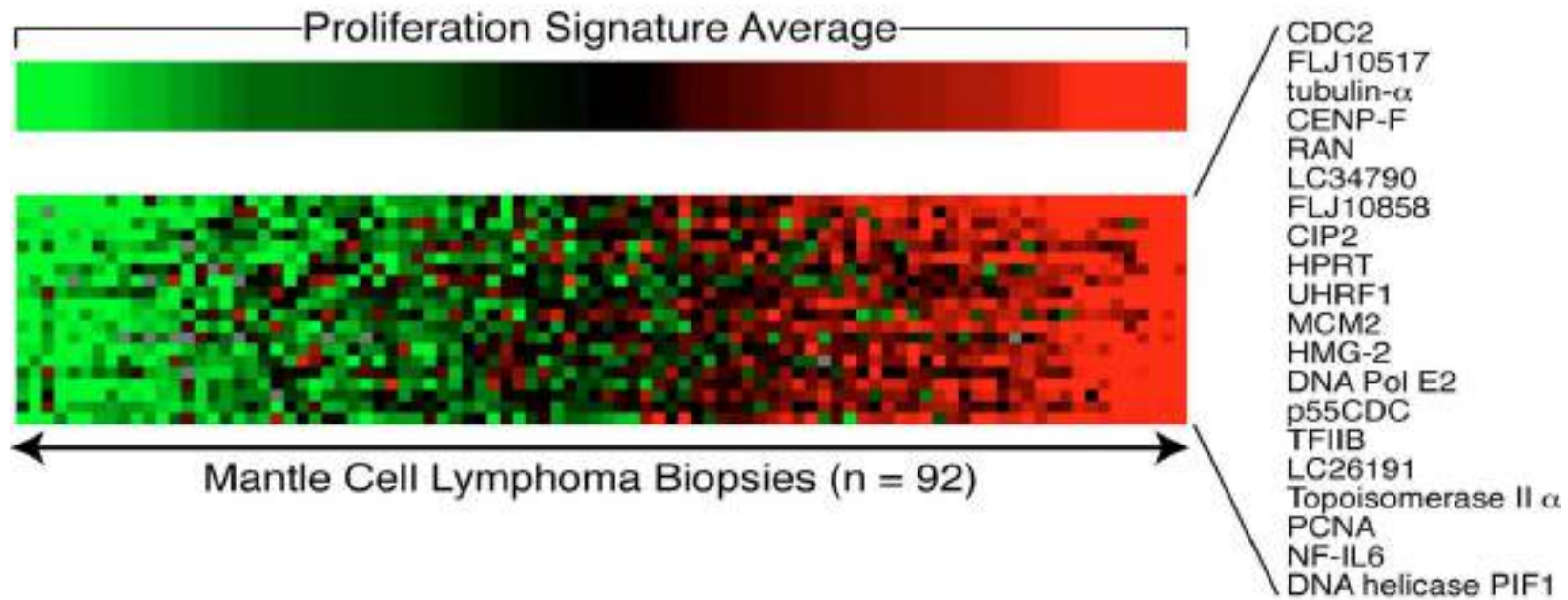
Eva Hoster, Andreas Rosenwald, Françoise Berger, Heinz-Wolfram Bernd, Sylvia Hartmann, Christoph Lohdrenkötter, Thomas F.E. Barth, Nicole Brusaferri, Stefano Pileri, Grzegorz Kowalczyk, Roman Kocot, Stephan Stögbauer, Rosanna Forconi, Catherine Thieblemont, Michael Hallek, Bernard Coiffier, Ursula Veithing-Kaiser, Rida Bouabdallah, Lothar Knaflitz, Michael Pferschy-Dachbaur, Christian Schmidt, Vincent Ribrag, Wolfgang Hiddemann, Michael Untch, Johann C. Klein-Nelmann, Olivier Hermine, Martin H. Dreyling, and Wolfram Klapper



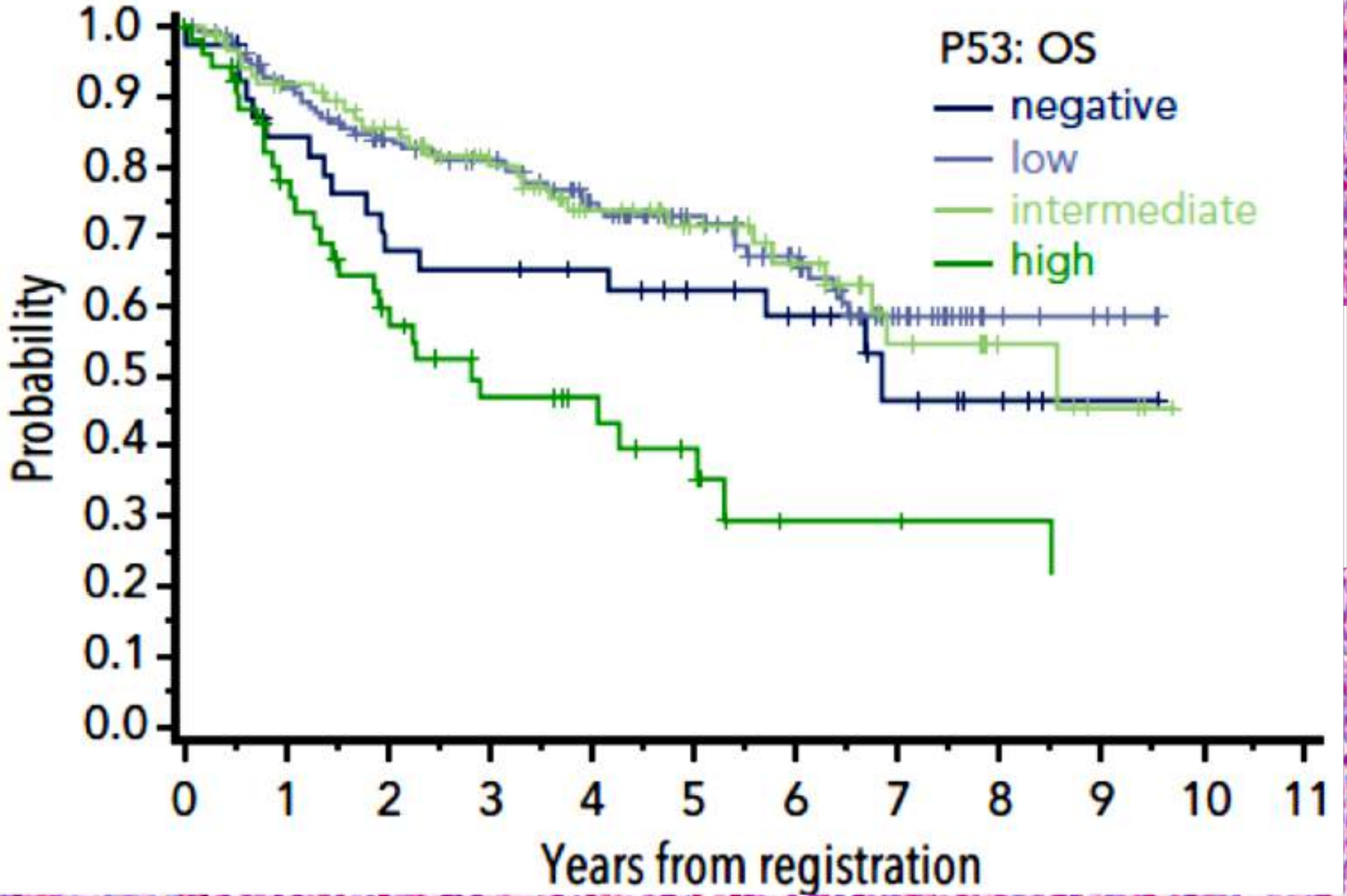
Ki-67 index



Variable Expression of Proliferation Signature Genes in Mantle Cell Lymphoma



**Rosenwald A et LLMPP, Cancer Cell 2003;
3(2):185-97.**



Virchows Arch. 2020 August ; 477(2): 259–267. doi:10.1007/s00428-020-02750-7.

Reproducibility of histologic prognostic parameters for mantle cell lymphoma: cytology, Ki67, p53 and SOX11

Giorgio A. Croci^{1,2}, Eva Hoster^{3,4}, Sílvia Bea^{5,6}, Guillem Clot^{5,6}, Anna Enjuanes^{5,6}, David W. Scott⁷, José Cabeçadas⁸, Luis Veloza⁹, Elias Campo^{5,6,9}, Erik Clasen-Linde¹⁰, Rashmi S. Goswami¹¹, Lars Helgeland¹², Stefano Pileri¹³, Grzegorz Rymkiewicz¹⁴, Sarah Reinke¹, Martin Dreyling⁴, Wolfram Klapper¹

LYMPHOID NEOPLASIA

Coding and noncoding drivers of mantle cell lymphoma identified through exome and genome sequencing

Prasath Pararajalingam,^{1,*} Krysta M. Coyle,^{1,*} Sarah E. Arthur,¹ Nicole Thomas,¹ Miguel Alcaide,¹ Barbara Meissner,^{2,3} Merrill Boyle,^{2,3} Quratulain Qureshi,¹ Bruno M. Grande,¹ Christopher Rushton,¹ Graham W. Slack,^{2,3} Andrew J. Mungall,⁴ Constantine S. Tam,^{5,4} Rishu Agarwal,⁵ Sarah-Jane Dawson,^{5,4} Georg Lenz,⁷ Sriram Balasubramanian,⁸ Randy D. Gascoyne,^{2,3} Christian Steidl,^{2,3} Joseph Connors,^{2,3} Diego Villa,^{2,3} Timothy E. Audas,¹ Marco A. Marra,^{2,3} Nathalie A. Johnson,⁹ David W. Scott,^{2,3} and Ryan D. Morin^{1,4}

¹Department of Molecular Biology and Biochemistry, Simon Fraser University, Burnaby, BC, Canada; ²BC Cancer Centre for Lymphoid Cancer and ³BC Cancer Research Centre, Vancouver, BC, Canada; ⁴Michael Smith Genome Sciences Centre, Vancouver, BC, Canada; ⁵Peter MacCallum Cancer Centre, Melbourne, VIC, Australia; ⁶University of Melbourne, Melbourne, VIC, Australia; ⁷Department of Medicine A, Hematology, Oncology, and Pneumology, University Hospital Münster, Münster, Germany; ⁸Janssen Research and Development, San Diego, CA; and ⁹Department of Medicine, Jewish General Hospital, Montreal, QC, Canada

KEY POINTS

- RNA-binding proteins with roles in regulating alternative splicing, *DAZAP1*, *EWSR1*, *HNRNPH1*, are frequently mutated in MCL.
- Most somatic *HNRNPH1* mutations are intronic and disrupt regulation of *HNRNPH1* through alternative splicing.

Mantle cell lymphoma (MCL) is an uncommon B-cell non-Hodgkin lymphoma (NHL) that is incurable with standard therapies. The genetic drivers of this cancer have not been firmly established, and the features that contribute to differences in clinical course remain limited. To extend our understanding of the biological pathways involved in this malignancy, we performed a large-scale genomic analysis of MCL using data from 51 exomes and 34 genomes alongside previously published exome cohorts. To confirm our findings, we resequenced the genes identified in the exome cohort in 191 MCL tumors, each having clinical follow-up data. We confirmed the prognostic association of *TP53* and *NOTCH1* mutations. Our sequencing revealed novel recurrent noncoding mutations surrounding a single exon of the *HNRNPH1* gene. In RNA-seq data from 103 of these cases, MCL tumors with these mutations had a distinct imbalance of *HNRNPH1* isoforms. This altered splicing of *HNRNPH1* was associated with inferior outcomes in MCL and showed a significant increase in protein expression by immunohistochemistry. We describe a functional role for these recurrent noncoding mutations in disrupting an autoregulatory feedback mechanism,

thereby deregulating *HNRNPH1* protein expression. Taken together, these data strongly imply a role for aberrant regulation of messenger RNA processing in MCL pathobiology. (*Blood*. 2020;136(5):572-584)

Circulating tumor DNA predicts therapeutic outcome in mantle cell lymphoma

Rahul Lakhotia,¹ Christopher Melani,¹ Kieron Dunleavy,² Stefania Pittaluga,³ Nakhle Saba,⁴ Liza Lindenberg,⁵ Esther Mena,⁵ Ethan Bergvall,⁶ Andrea Nicole Lucas,⁷ Allison Jacob,⁸ Erik Yusko,⁸ Seth M. Steinberg,⁹ Elaine S. Jaffe,³ Adrian Wiestner,¹⁰ Wyndham H. Wilson,^{1*} and Mark Roschewski^{1*}

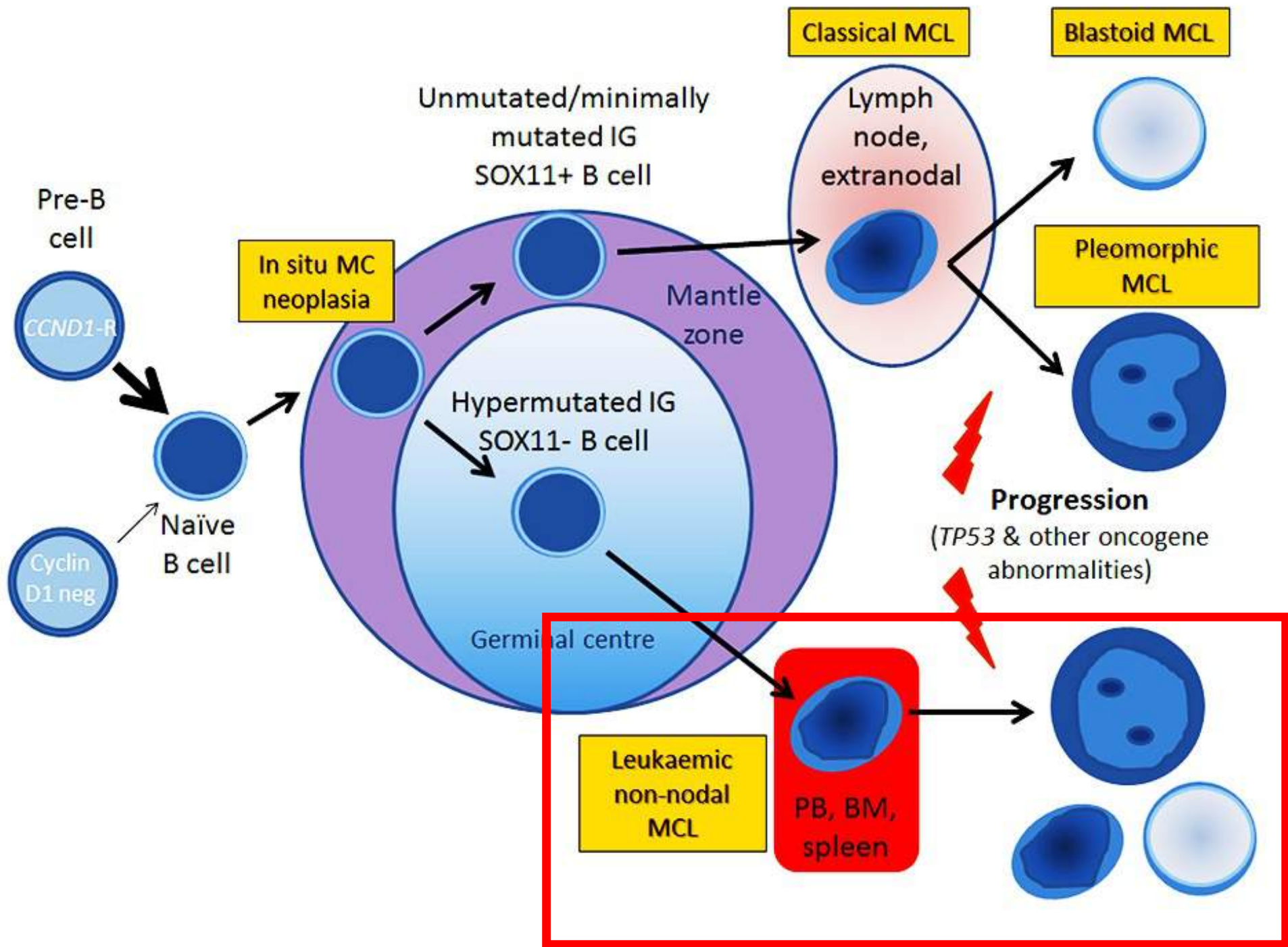


Zanubrutinib in relapsed/refractory mantle cell lymphoma: long-term efficacy and safety results from a phase 2 study

Yuqin Song,¹ Keshu Zhou,² Dehui Zou,³ Jianfeng Zhou,⁴ Jianda Hu,⁵ Haiyan Yang,⁶ Huilai Zhang,⁷ Jie Ji,⁸ Wei Xu,⁹ Jie Jin,¹⁰ Fangfang Lv,¹¹ Ru Feng,¹² Sujun Gao,¹³ Haiyi Guo,¹⁴ Lei Zhou,¹⁵ Jane Huang,¹⁶ William Novotny,¹⁶ Pil Kim,¹⁶ Yiling Yu,¹⁴ Binghao Wu,¹⁴ and Jun Zhu¹

KEY POINTS

- **Zanubrutinib demonstrated deep and durable responses and a favorable safety profile in R/R MCL at median 35.3 months follow-up.**
- **Zanubrutinib provided a high response rate (84% [78% CR]) and extended PFS (median 33.0 months) in patients with R/R MCL.**

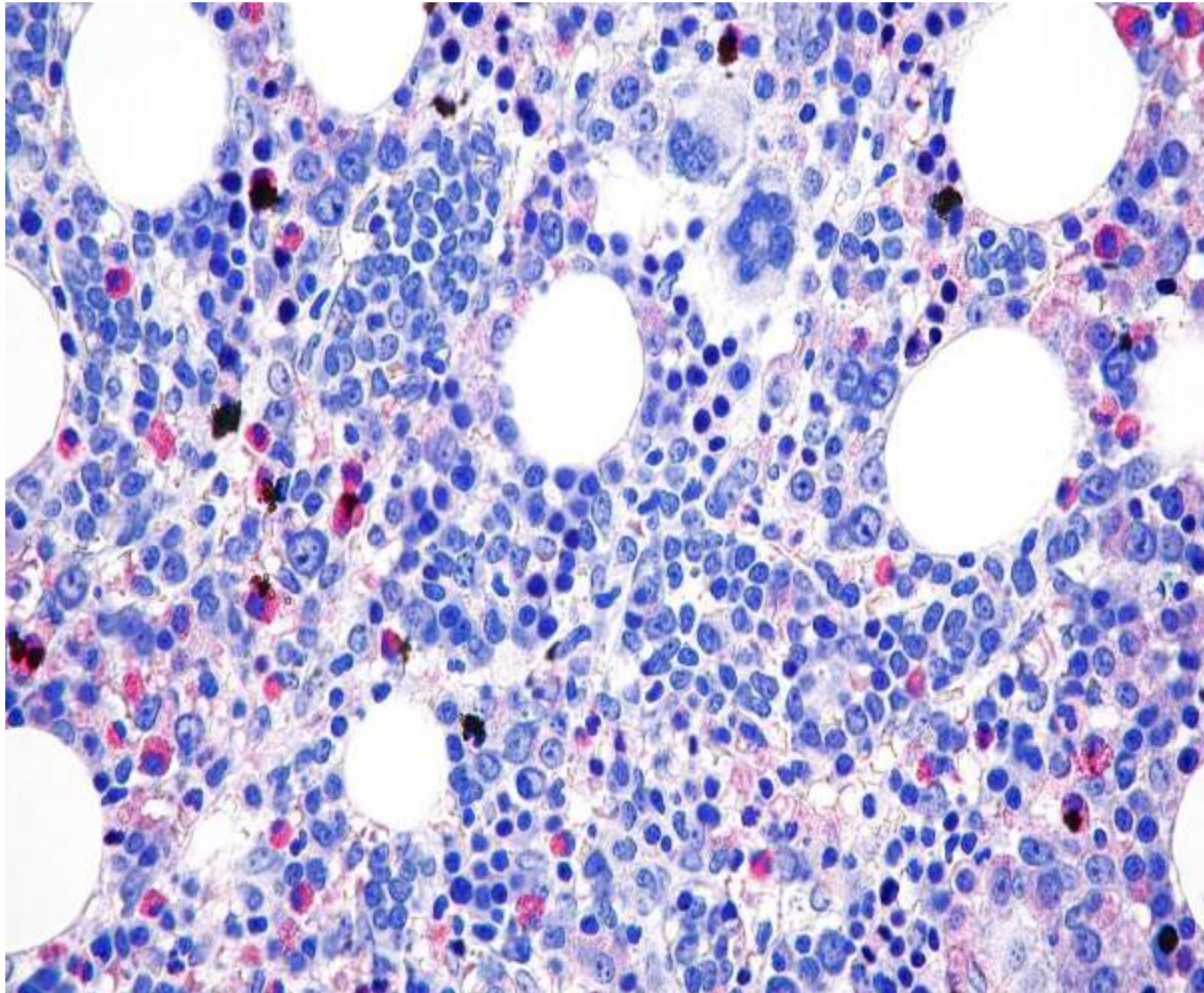


Genomic and Gene Expression Profiling Defines Indolent Forms of Mantle Cell Lymphoma

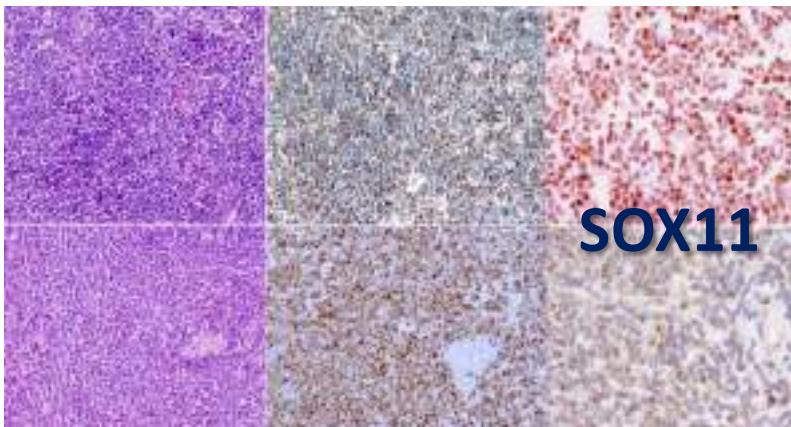
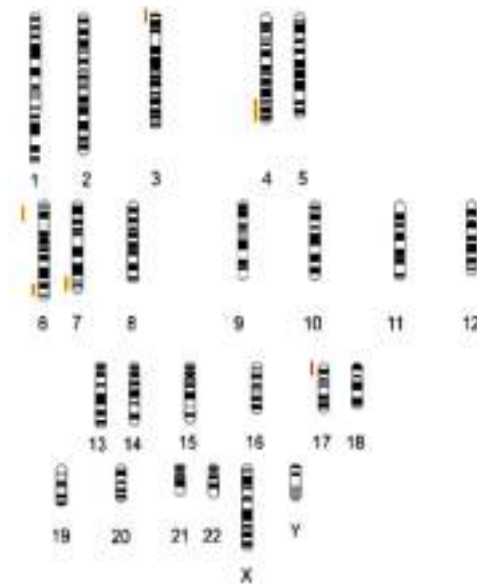
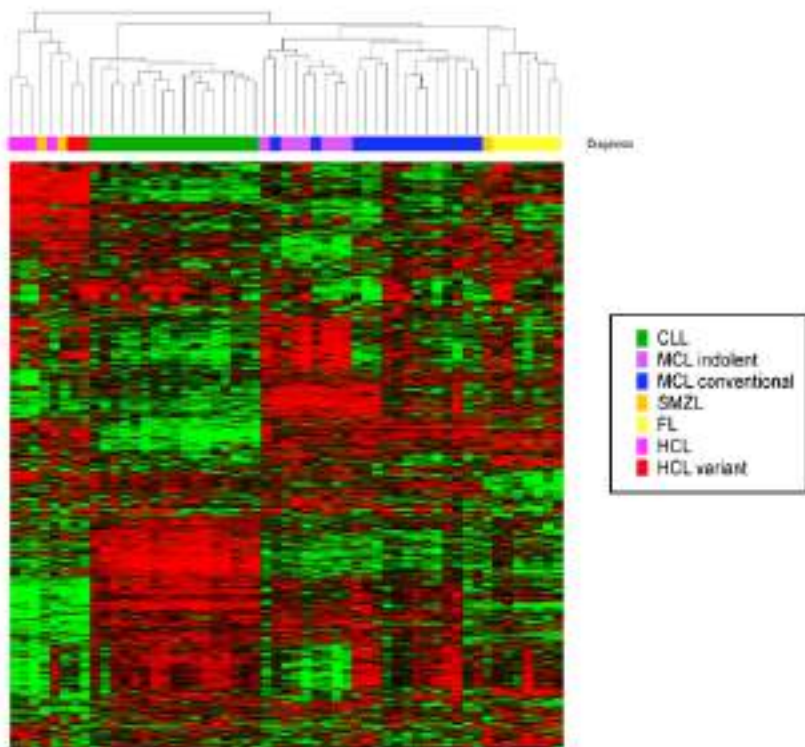
Verónica Fernández¹, Olga Salamero², Blanca Espinet³, Francesc Solé³, Cristina Royo¹, Alba Navarro¹, Francisca Camacho⁴, Silvia Beà¹, Elena Hartmann⁵, Virginia Amador¹, Luis Hernández¹, Claudio Agostinelli⁶, Rachel L. Sargent⁷, Maria Rozman¹, Marta Aymerich¹, Dolors Colomer¹, Neus Villamor¹, Steven H. Swerdlow⁷, Stefano A. Pileri⁶, Francesc Bosch², Miguel A. Piris⁴, Emili Montserrat², German Ott⁸, Andreas Rosenwald⁵, Armando López-Guillermo², Pedro Jares¹, Sergi Serrano³, and Elías Campo¹

Molecular Subsets of Mantle Cell Lymphoma Defined by the *IGHV* Mutational Status and SOX11 Expression Have Distinct Biologic and Clinical Features

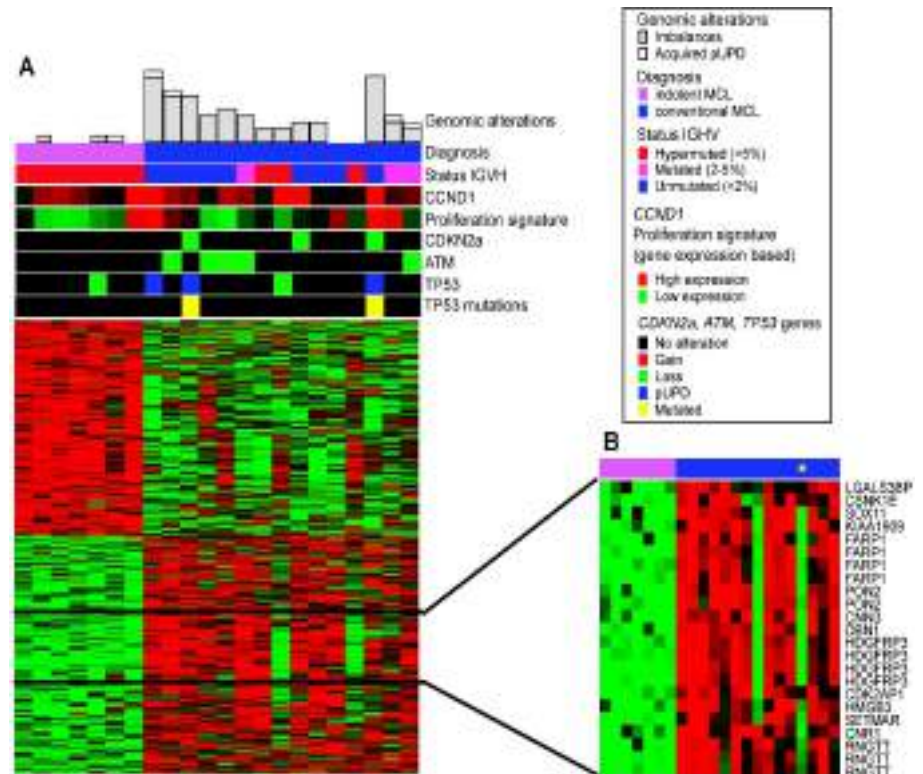
Alba Navarro¹, Guillem Clot¹, Cristina Royo¹, Pedro Jares¹, Anastasia Hadzidimitriou⁴, Andreas Agathangelidis^{4,5}, Vasilis Bikos⁴, Nikos Darzentas⁴, Theodora Papadaki⁷, Itziar Salaverria^{1,8}, Magda Pinyol¹, Xavier Puig², Jara Palomero¹, Maria Carmela Vegliante¹, Virginia Amador¹, Alejandra Martinez-Trillos¹, Lenka Stefancikova¹², Adrian Wiestner¹³, Wyndham Wilson¹³, Christiane Pott⁹, Maria Jose Calasanz³, Nicola Trim¹⁴, Wendy Erber¹⁵, Birgitta Sander¹⁶, German Ott¹⁰, Andreas Rosenwald¹¹, Dolors Colomer¹, Eva Giné¹, Reiner Siebert⁸, Armando Lopez-Guillermo¹, Kostas Stamatopoulos^{4,6}, Silvia Beà¹, and Elías Campo¹

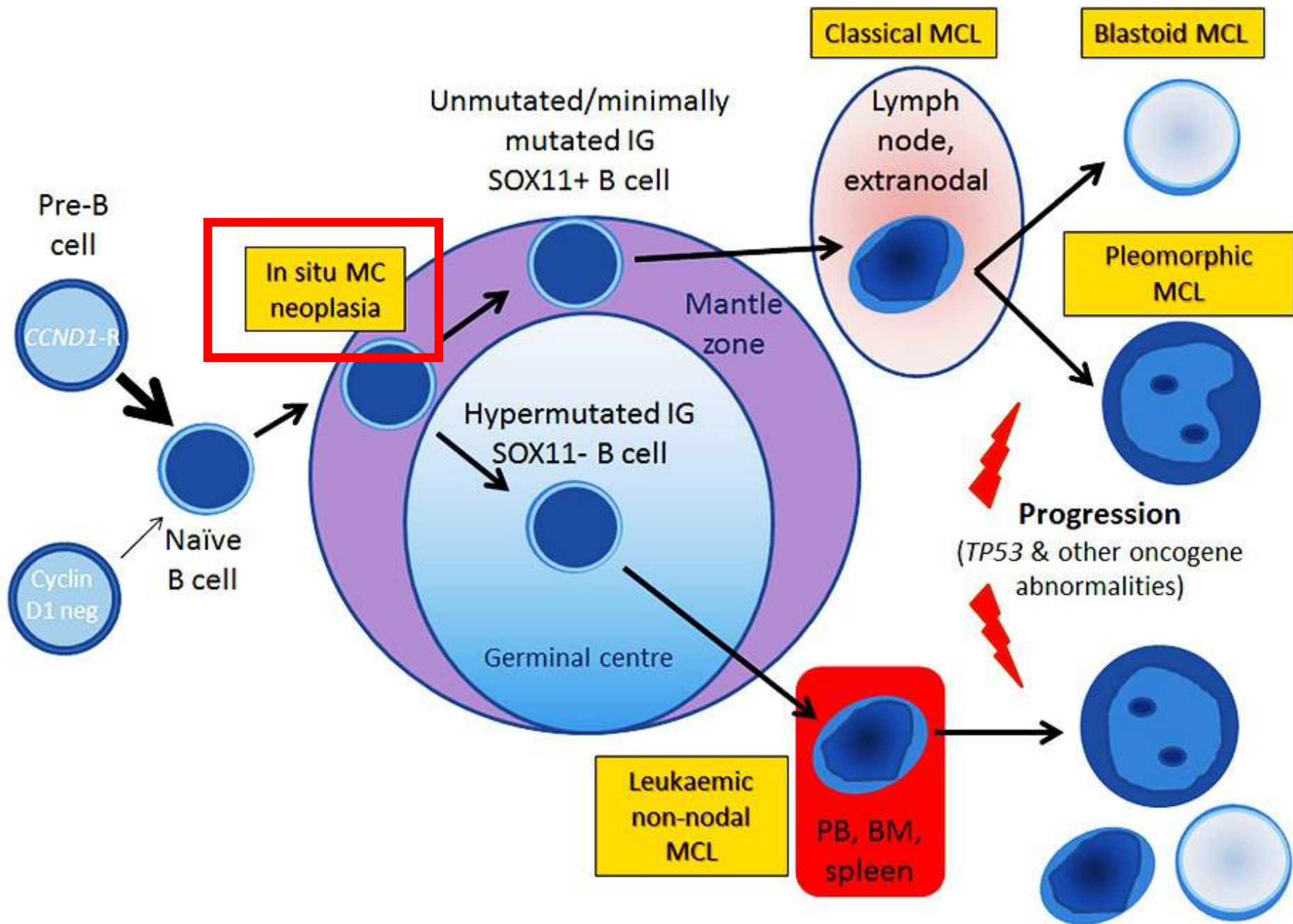


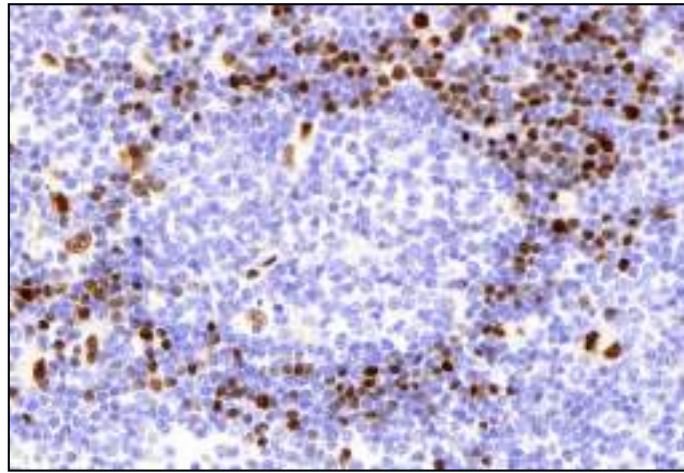
	cMCL (n=15)	iMCL (n=12)	P value
B symptoms (%)	33	0	0.03
Non-ambulatory performance status ECOG≥2 (%)	70	0	0.01
Nodal presentation (lymph nodes >1 cm) (%)*	93	17	<0.001
High serum LDH* (%)	46	0	0.03
Intermediate or high-risk MIPI	46	0	0.016
Morphology	13	67	0.007
Small cell (%)	74	33	
Classical	13	-	
Blastoid			
<i>IGHV</i> gene hypermutations (>5%)	20	70	< 0.04
Genomic Profile			
1. imbalance	13	100	<0.001
≥ 2 imbalances	87	0	
Chemotherapy at any time (%)	100	17	
Dead patients (%)	47	0	<0.001
5-year overall survival (%)	49	100	0.03



LN MCL shows a specific gene signature and SOX11 negativity







LN with Cyclin D1+
In Situ Pattern



SOX11 negative

May be CD5 negative
Rare event: <1% of LNs
Low risk of Progression (<10%)

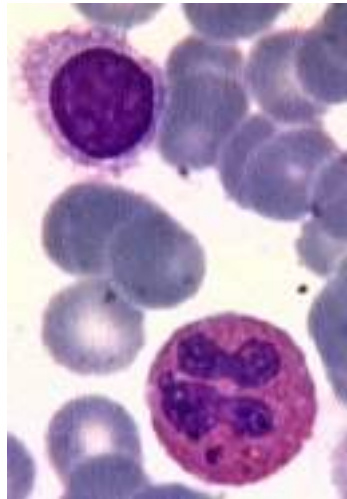
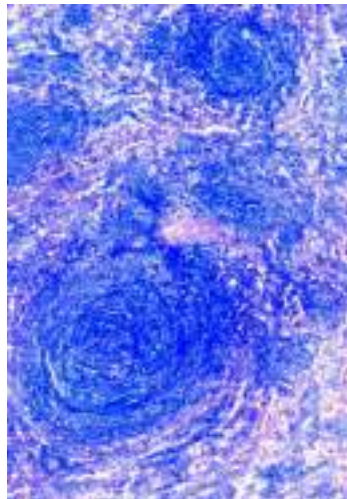
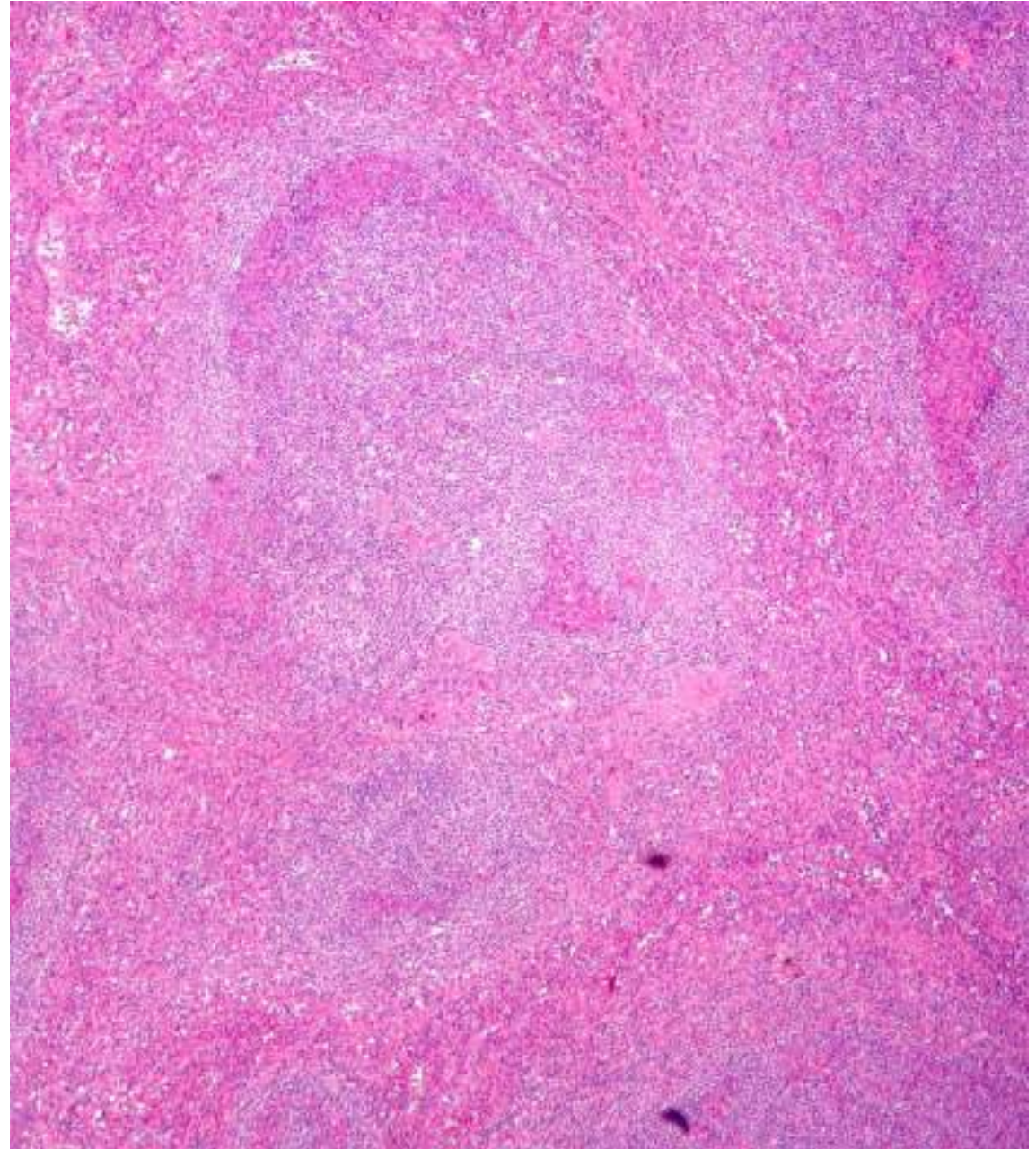
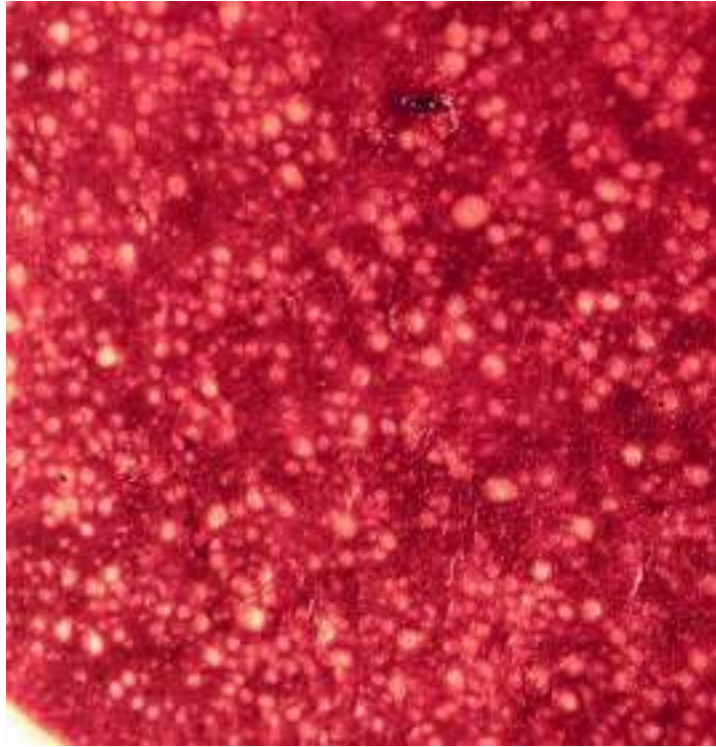
SOX11 positive

More often CD5 positive
Higher risk of progression
Similar pattern can be seen
at relapse or at distant sites

Splenic marginal zone lymphoma

Definition

Splenic marginal zone lymphoma (SMZL) is a B-cell neoplasm composed of small lymphocytes that surround and replace the splenic white pulp germinal centres, efface the follicle mantle, and merge with a peripheral (marginal) zone of larger cells, including scattered transformed blasts; both small and larger cells infiltrate the red pulp. Splenic hilar lymph nodes and bone marrow are often involved; lymphoma cells are frequently found in the peripheral blood as villous lymphocytes.



Phenotype

CD19, CD20, CD22, CD79a, CD79b +

IgM+

IgD+

MNDA+

DBA44+/-

IRF4 -/+

BCL2+ (weak)

Annexin A-

CD5- (exceptions)

CD23-

Cyclin D1 –

SOX11-

CD200 –

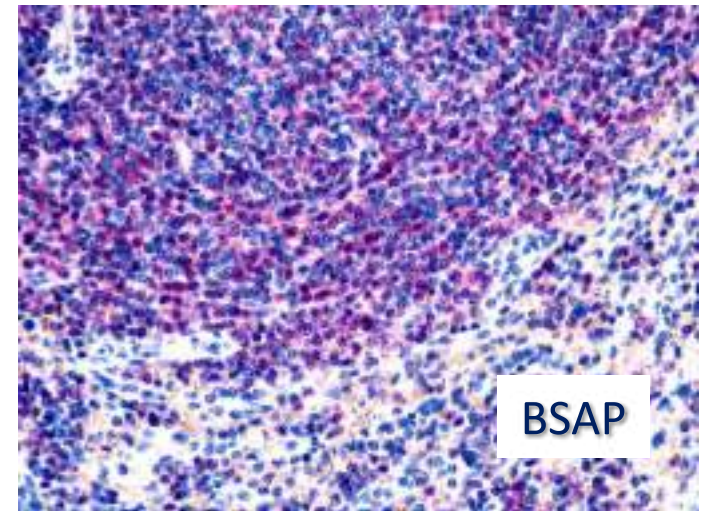
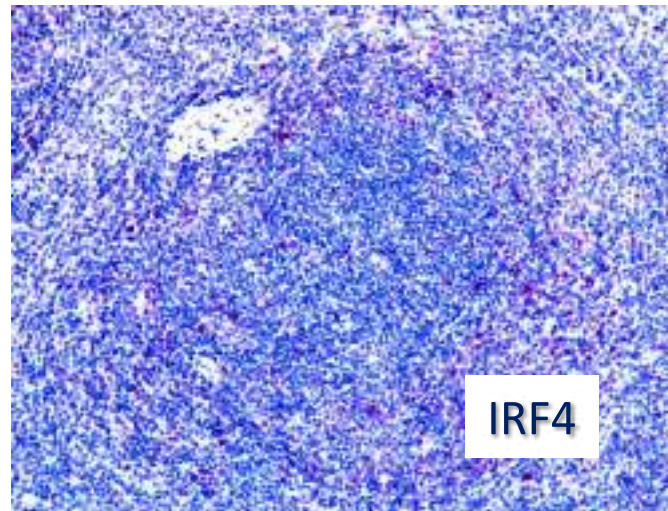
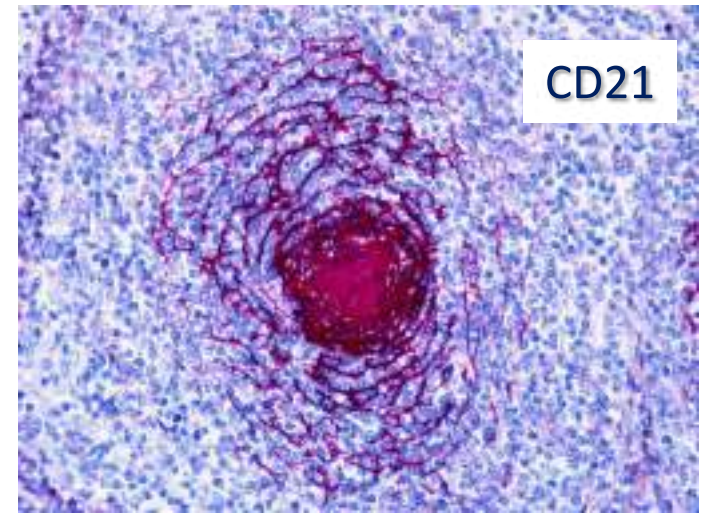
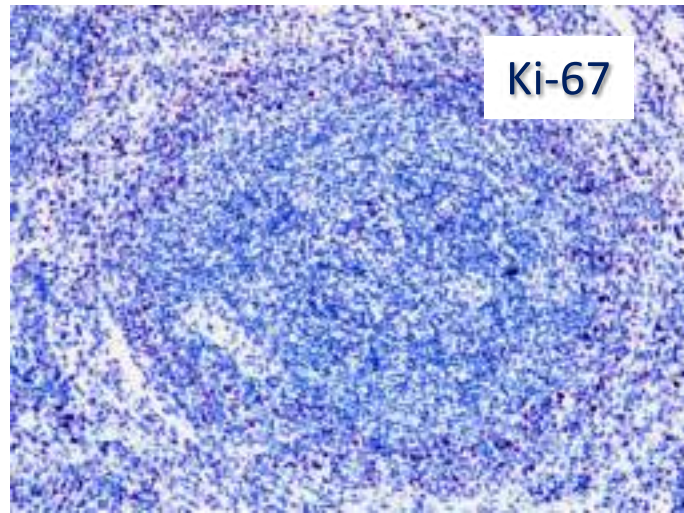
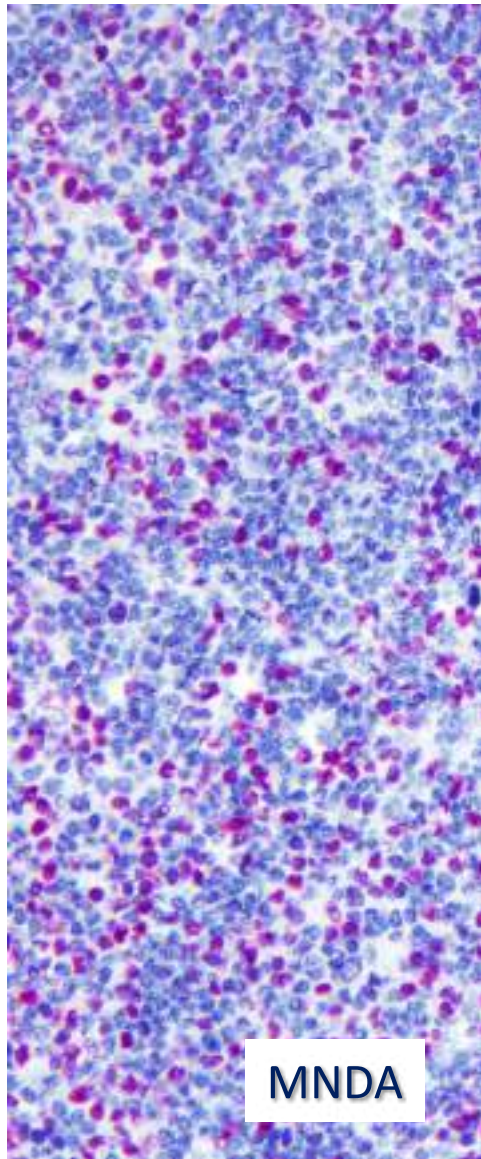
LEF1 –

IRTA1, T-bet -

CD10, BCL6, LMO2 –

Ki-67: variable



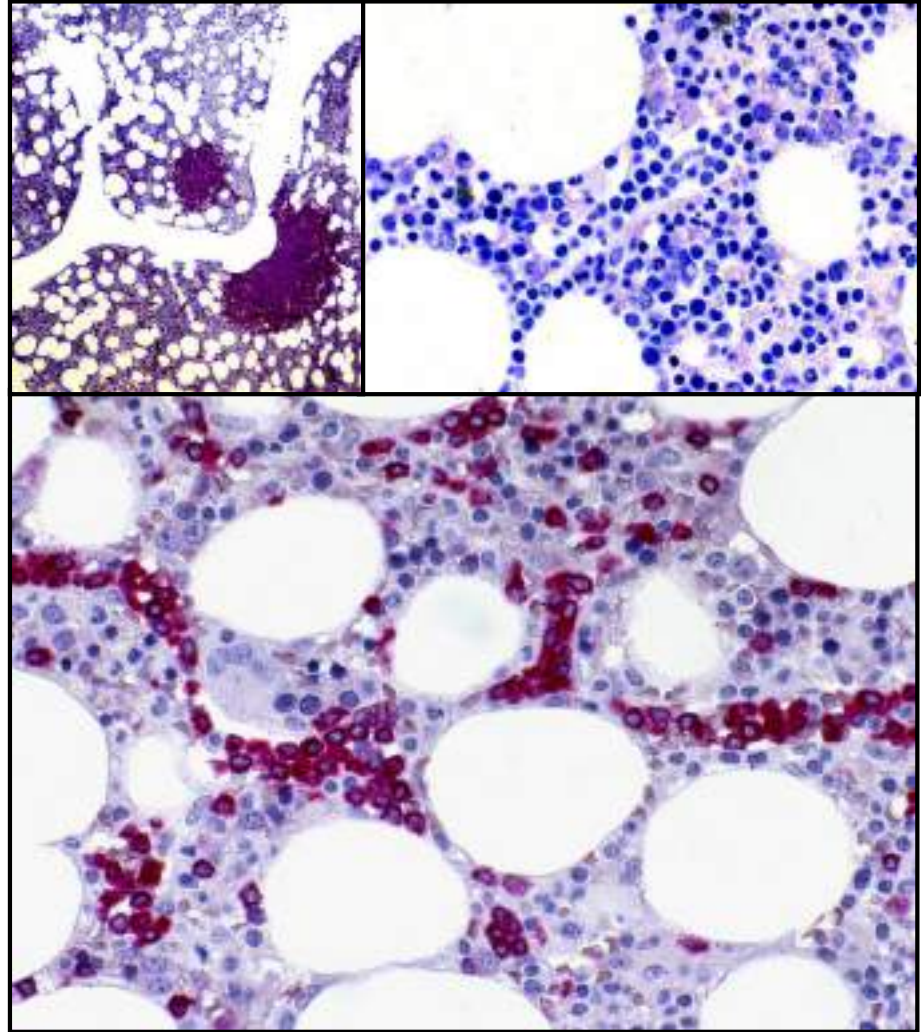


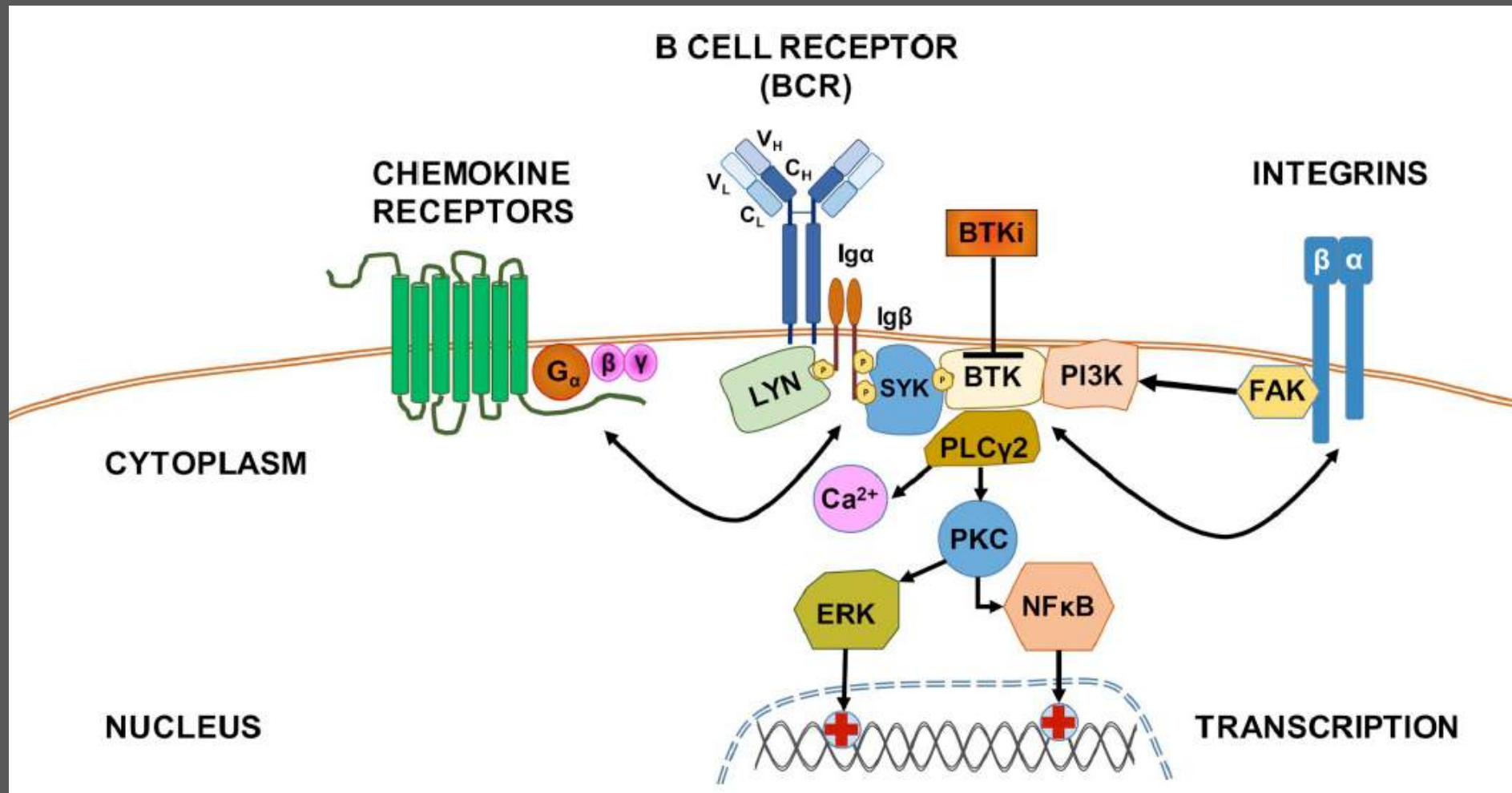
BM involvement

nodular,

Interstitial.

Intra-sinusoidal

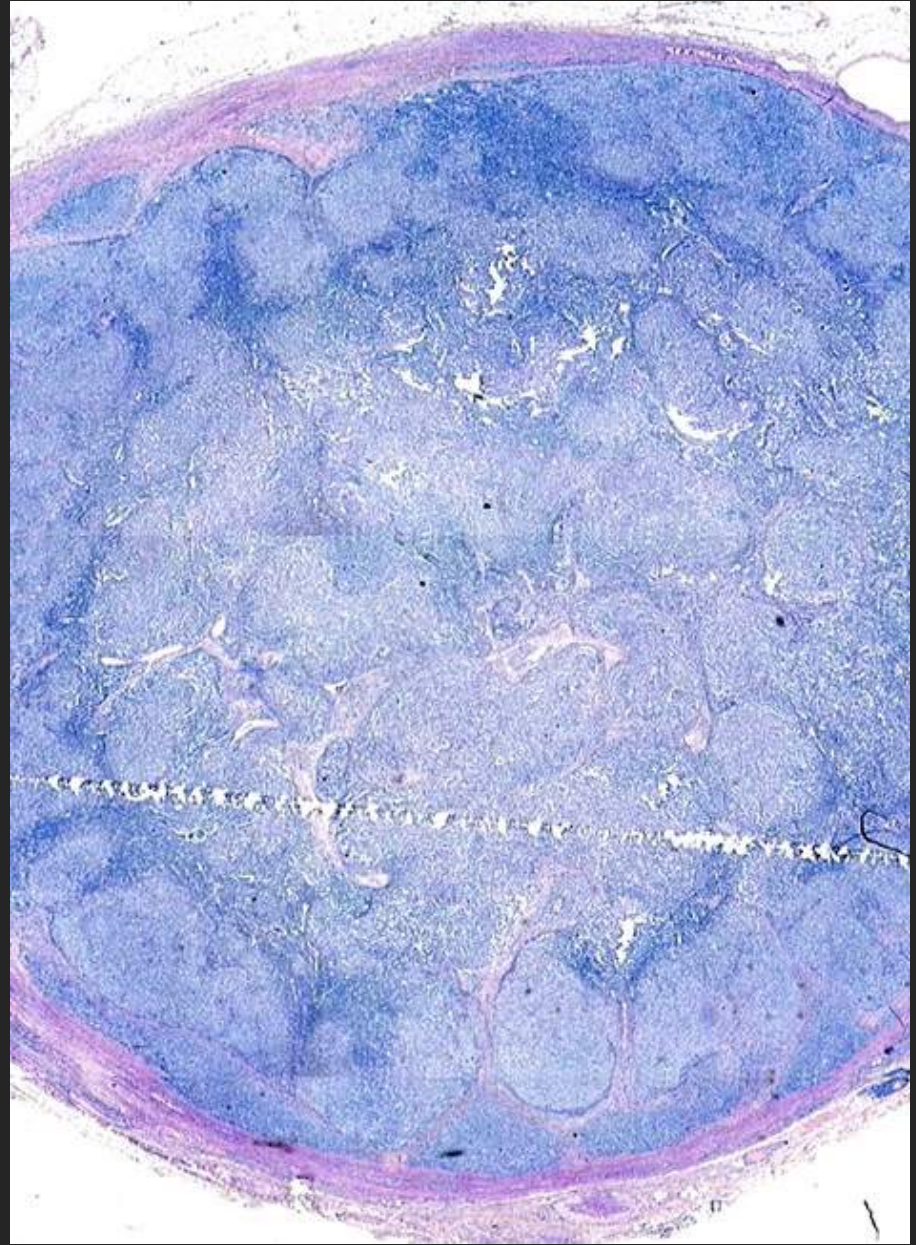
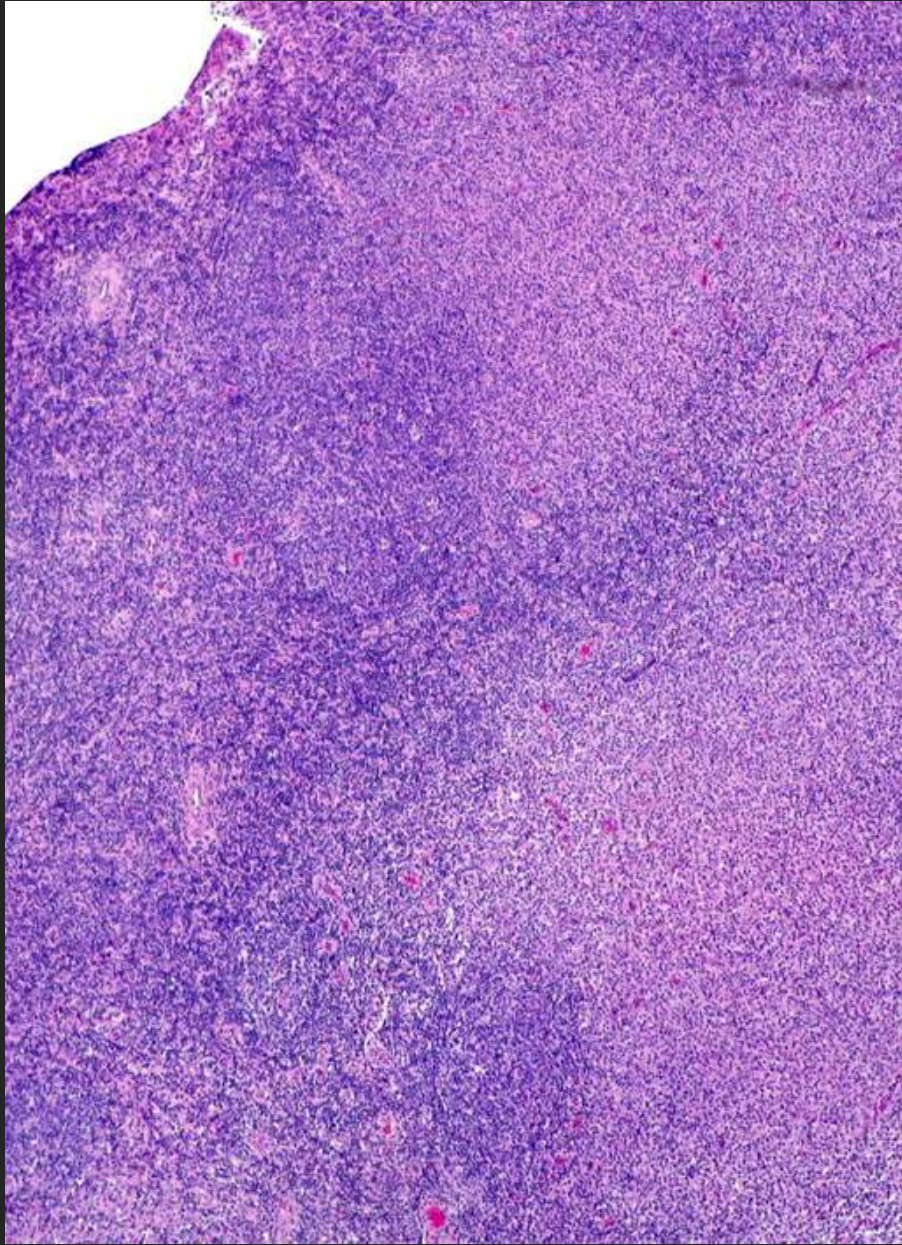


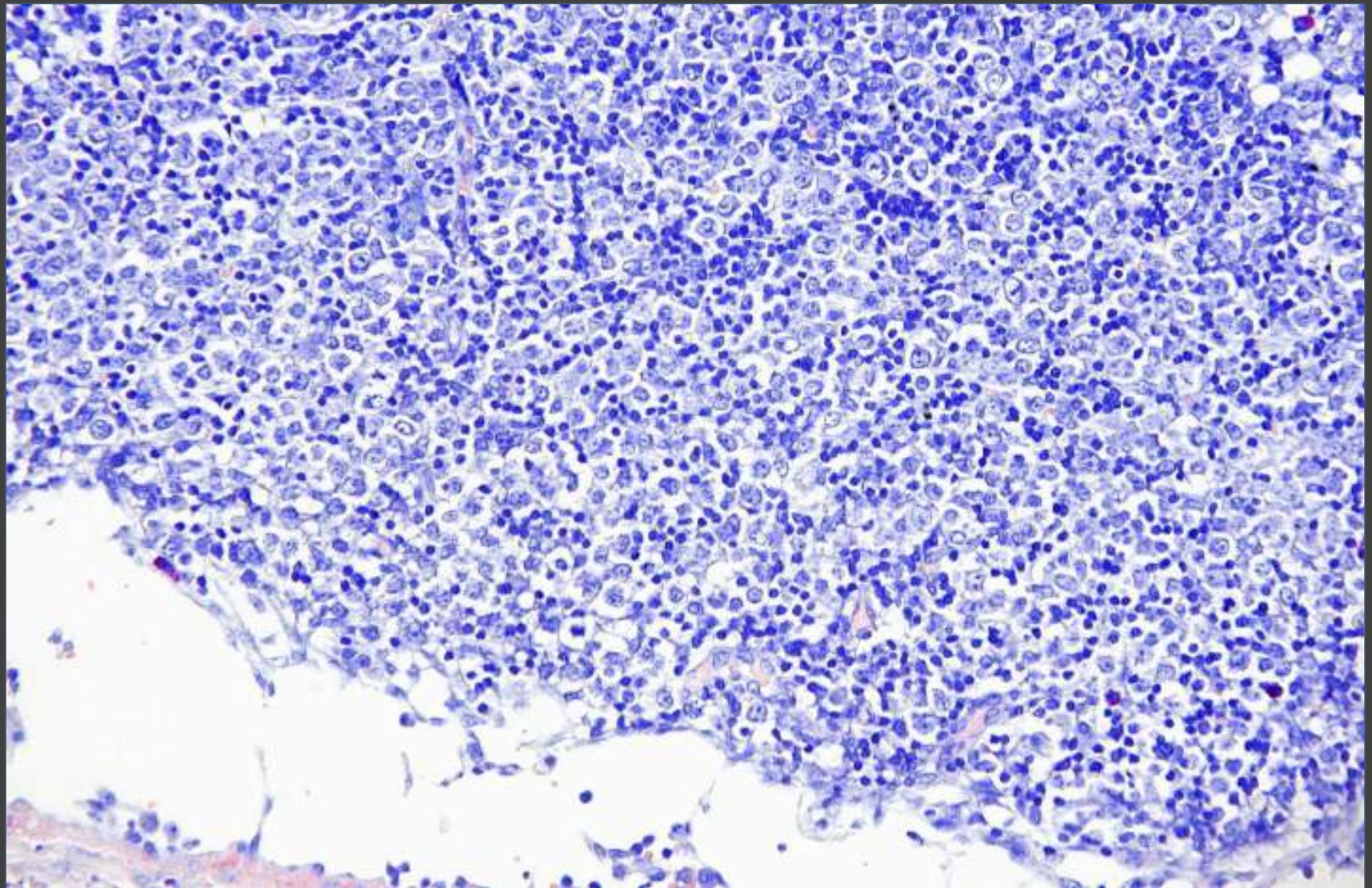


Nodal marginal zone lymphoma

Definition

Nodal marginal zone lymphoma (NMZL) is a primary nodal B-cell neoplasm that morphologically resembles lymph nodes involved by marginal zone lymphoma (MZL) of the extranodal or splenic types, but without evidence of extranodal or splenic disease.





Phenotype

CD19, CD20, CD22, CD79a, CD79b +

IgM/G+

IgD-/+

IRTA1+, T-bet+ (monocytoid); MNDA+ (splenic-type)

IRF4-/+ (plasma cell differentiation)

BCL2+ (weak)

CD5- (rarely +)

CD23-

Cyclin D1 –

SOX11-

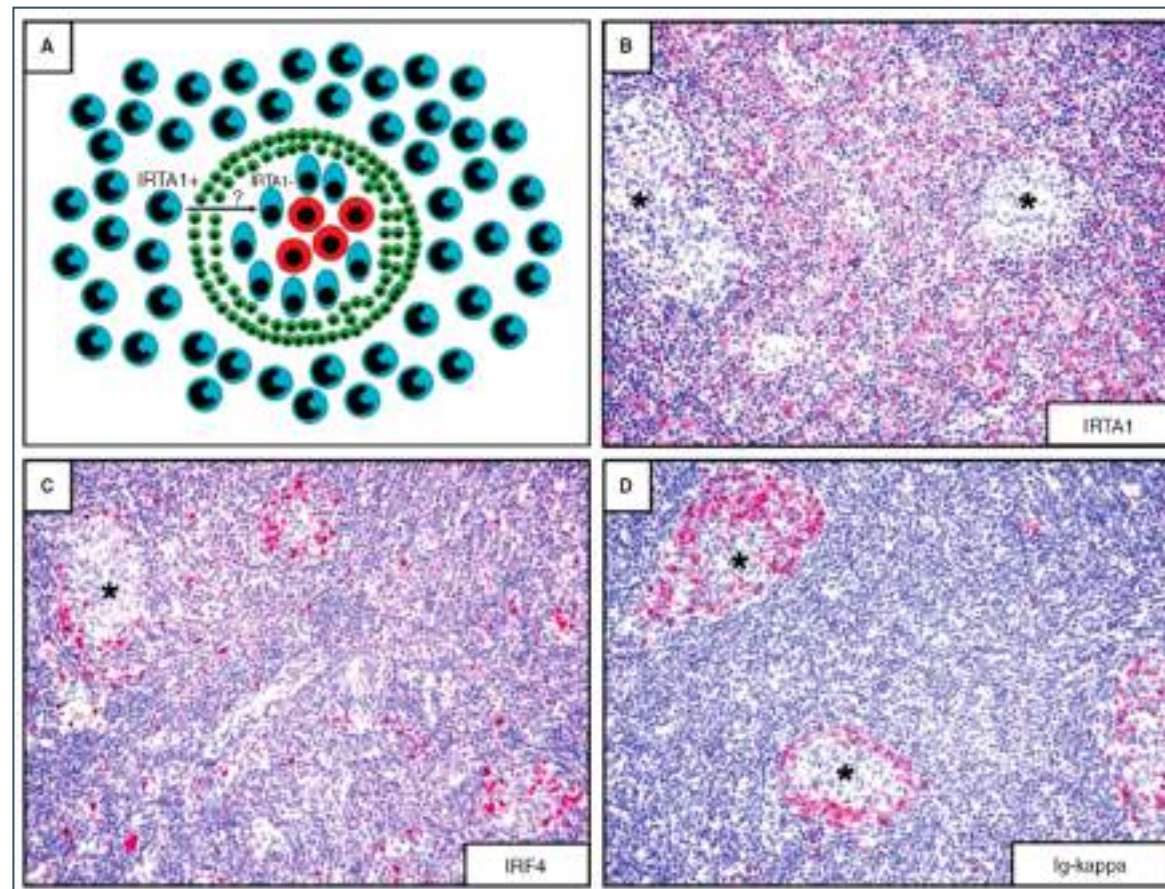
CD200 –

LEF1 –

CD10, BCL6 (colonization), LMO2 –

Ki-67: variable





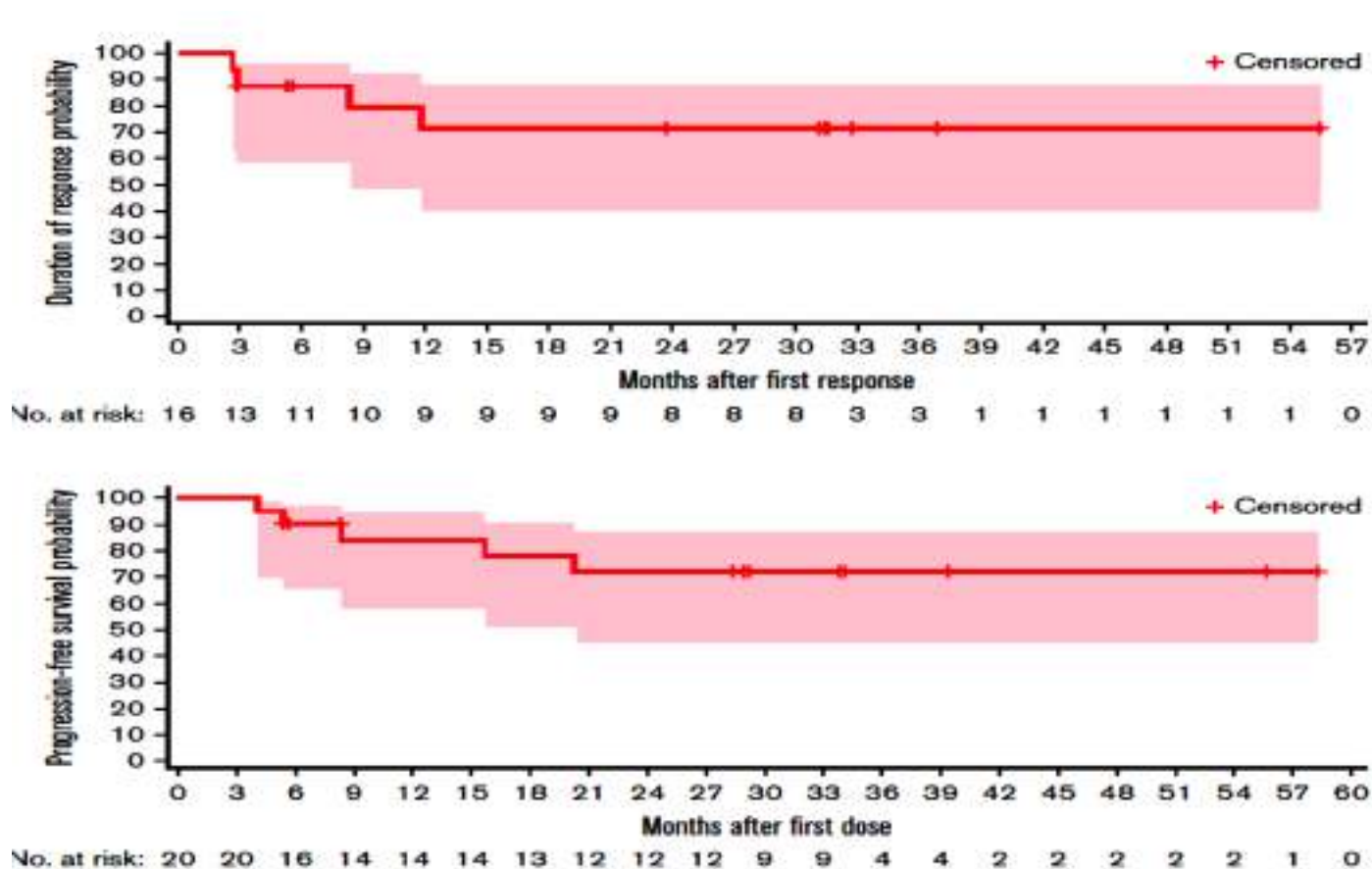
Histopathology 2012, 61, 930-941. DOI: 10.1111/j.1365-2559.2012.04289.x

IRTA1 is selectively expressed in nodal and extranodal marginal zone lymphomas

Brunangelo Falini, Claudio Agostinelli,¹ Barbara Bigerna, Alessandra Pucciarini, Roberta Pacini, Alessia Tabarrini, Flavio Falcinelli, Milena Piccioli,¹ Marco Paulli,² Marcello Gambacorta,³ Maurilio Ponzoni,⁴ Enrico Tiacchi, Stefano Ascani,⁵ Maria Paola Martelli, Riccardo Dalla Favera,⁶ Harald Stein⁷ & Stefano A Pileri¹

Zanubrutinib monotherapy in relapsed/refractory indolent non-Hodgkin lymphoma

Tyrel Phillips,¹ Henry Chan,² Constantine S. Tam,^{3,4} Alessandra Tedeschi,⁵ Patrick Johnston,⁶ Sung Yong Oh,⁷ Stephen Opat,^{8,9} Hyeon-Seok Eom,¹⁰ Heather Allewelt,¹¹ Jennifer C. Stern,¹² Ziwen Tan,¹¹ William Novotny,¹¹ Jane Huang,¹³ and Judith Trotman^{14,15}



V. Tabanelli, S. Fiori, A. Calleri, F. Melle, G. Motta, S. Mazzara,
M.R. Sapienza, M. Del Corvo, P. Antoniotti, M. Giuffrida, G.
Procida, V. Rossi, E Derenzini

