



CAR-TALKING

News dal mondo CAR-T

Milano, Starhotels E.c.ho.
4 aprile 2023

Caso Clinico

DLBCL

Stefania Bramanti
Sezione di Terapia Cellulare
IRCCS Istituto Clinico Humanitas

Clinical presentation

Onset - October 2020

Symptoms and signs

- Weight loss (20 kg from July)
- Vomiting



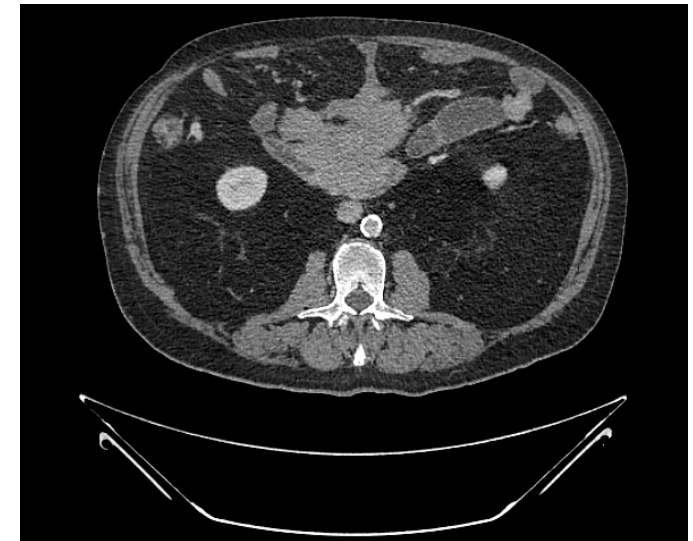
CT scan abdomen

- 10 cm mesenteric lymphadenopathy
- Duodenal thickening

F.B. 71 y.o., male

Comorbidity

- Arterial hypertension
- Dyslipidemia
- Type 2 Diabetes
- Occlusive peripheral arterial disease



Diagnosis and staging



EGDS

Hyperemic and edematous
mucosa
Severe duodenal stenosis

Biopsy

DLBCL NOS
Ki67 70%
BCL2 traslocation
p53 mut

PET-scan and CT scan

No other localization

Bone marrow biopsy: negative

DLBCL, GC type

Myc -, BCL2 traslocation, p53 mut
Stage IIEBX

CNS-IPI II

R-IPI I

IPI II

NCCN-IPI IV

First line therapy and relapse

First line treatment

Oct – Dec 2020 R-CHOP x 3 cycles

Jan 2020 Sars-Cov2 pneumonia and long-term positivity

4 March 2020 Negativization

PET and CT scan reevaluation: CR (DS3; 4 cm x 4 cm)

Age, Comorbidity and Complete Response achievement
→ strict follow-up

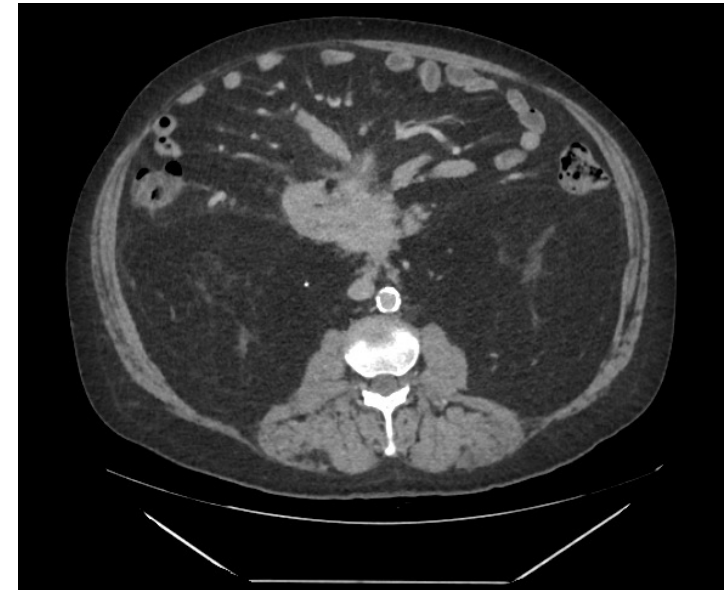May 2022 – Relapse

Clinical presentation: vomiting and nausea

CT scan: enlargement of mesenteric lesion 10 x 6 cm

PET scan: mesenteric and duodenal lesion (DS5)

Biopsy: DLBCL relapse



Second line therapy

May 2022 - ICH collegial discussion

CAR-T cell therapy predisposition
II line: R-Gemox
Early revaluation

Second line treatment

31/05/2022 Apheresis

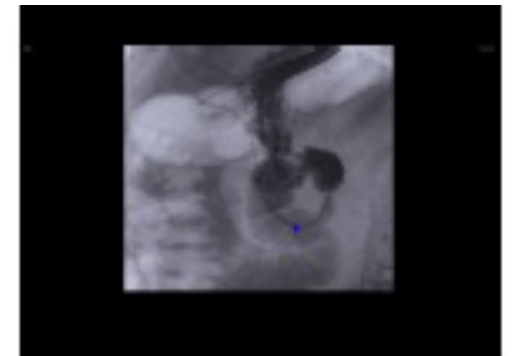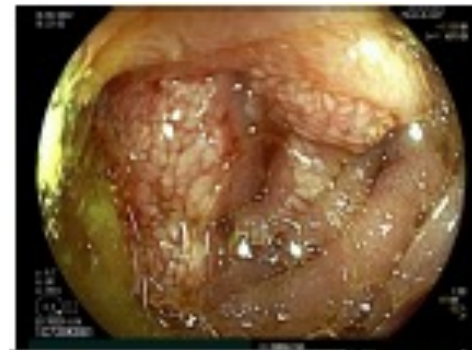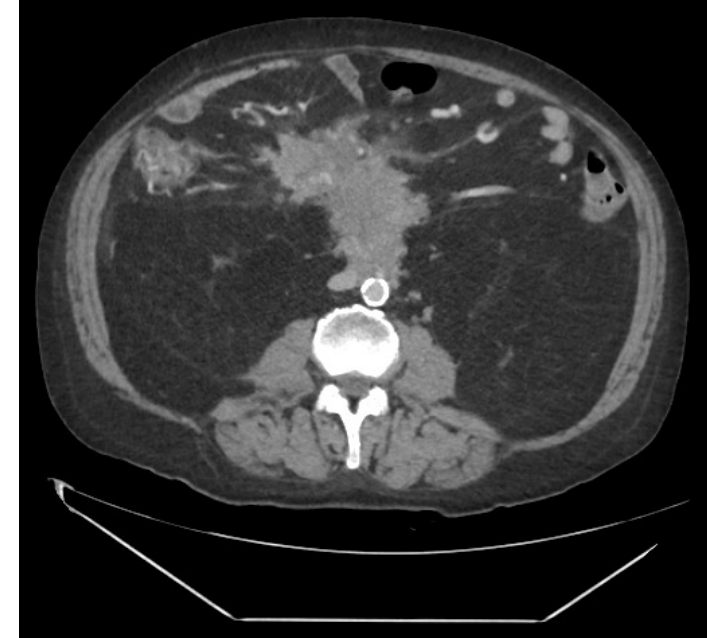
8/06/2022 – 02/07/2022 hospitalization:

Prerenal AKI and vomiting

R-Gemox

Clinical progression → duodenal bypass (endoscopy)

17/7/2022 PET scan: SD



CAR-T and +30/+60 revaluation

July 2022

August 2022

September 2022

October 2022

CAR-T infusion Hospitalisation - 27 July – 08 Aug

Product: Tisagenlecleucel (Kymriah)

Conditioning: Flu-Cy

Complications: CRS G0, ICANS0, Neutropenia G3

+ 30d PET scan revaluation

RC (DS3) → + 60d early revaluation

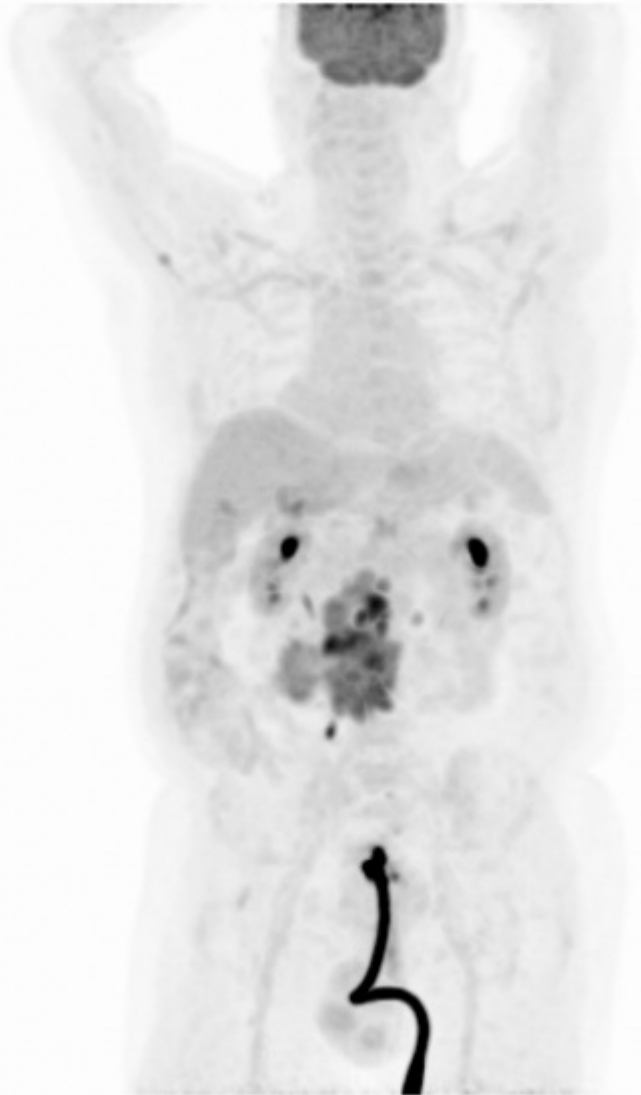
+ 60d PET scan revaluation

RC (DS3) → + 90d revaluation

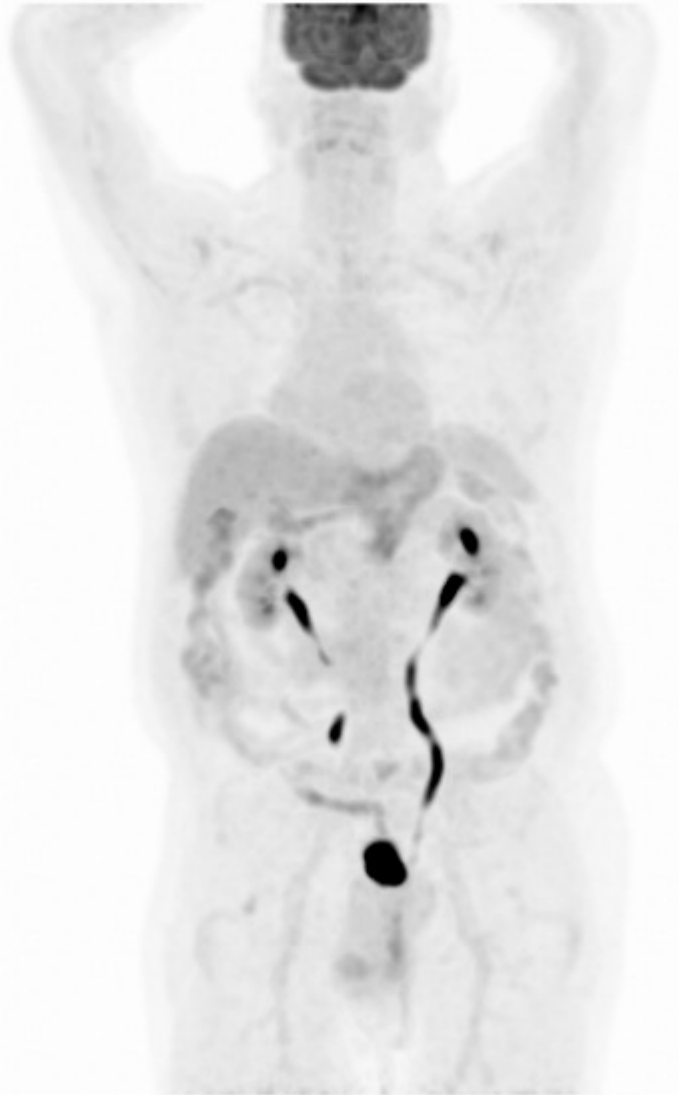
+ 90d PET scan revaluation

RC (DS2)

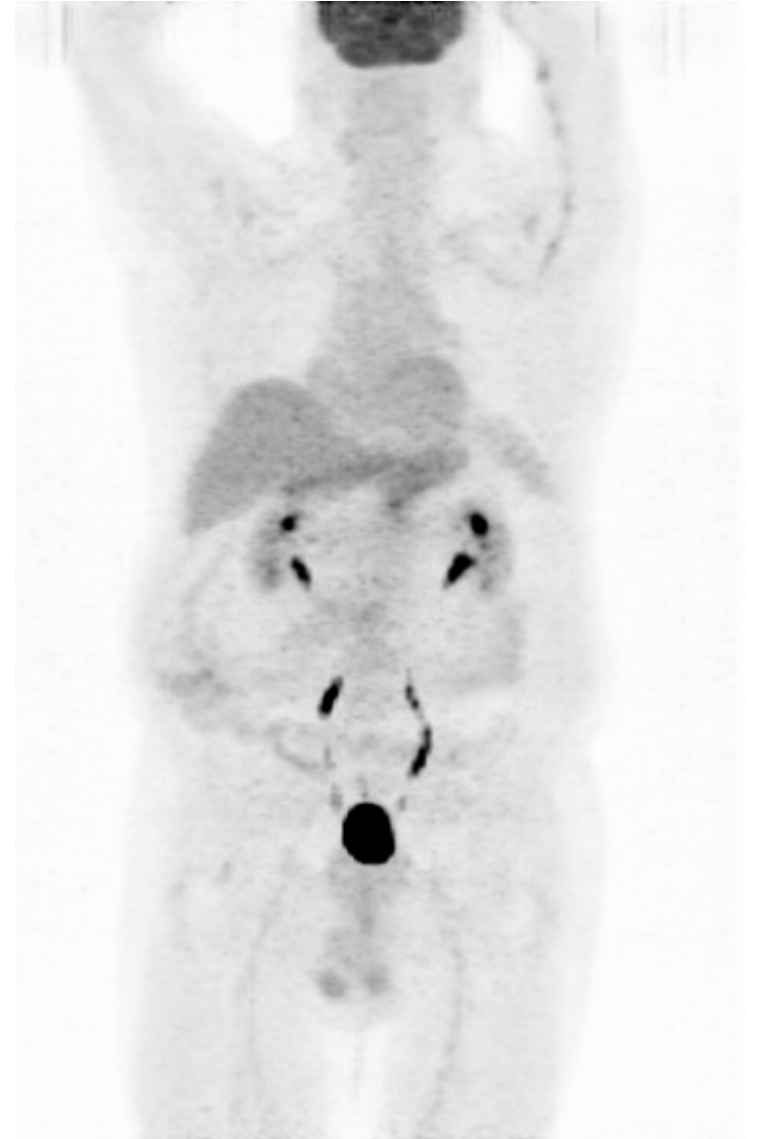
PET-tb pre CAR-T cell therapy



PET-tb +30d



PET-tb +60d



Last follow up

February 2023

+ 190 from CAR-T cell therapy

Well being at home, apyretic.

Normal blood count, normal hepatorenal function, PCR negative.

+180d PET scan revaluation → RC (DS2)

CAR-T

TEAM

Unità Clinica

Armando Santoro
Stefania Bramanti
Chiara De Philippis
Daniele Mannina

Farmacia

Gabriella Pieri
Martina Roperti



Unità di aferesi

Daniele Girardi
Elena Tirea
Annalisa Palladina

Anestesisti e Neurologi

Elena Costantini
Umberto Pensato

Radioterapia

Pierina Navarria

Laboratorio di manipolazione cellulare

Rossana Capizzutto
Inna Timofeeva
Laura Rondini

Trial Office

Laura Rossi
Elisa Carra

Infettivologi

Linda Bussini
Michele Bartoletti

HUMANITAS
HOSPITALS